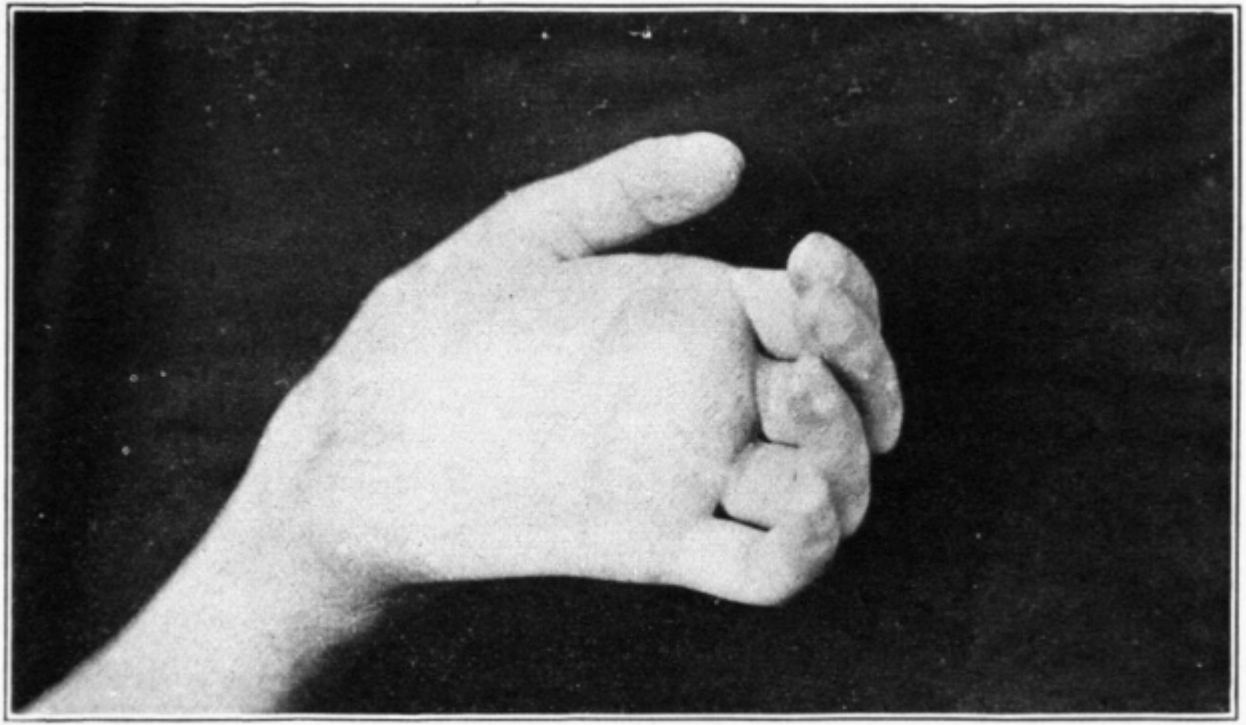

FIG. 119.—Partial lesion of whole brachial plexus, affecting chiefly posterior and outer cords