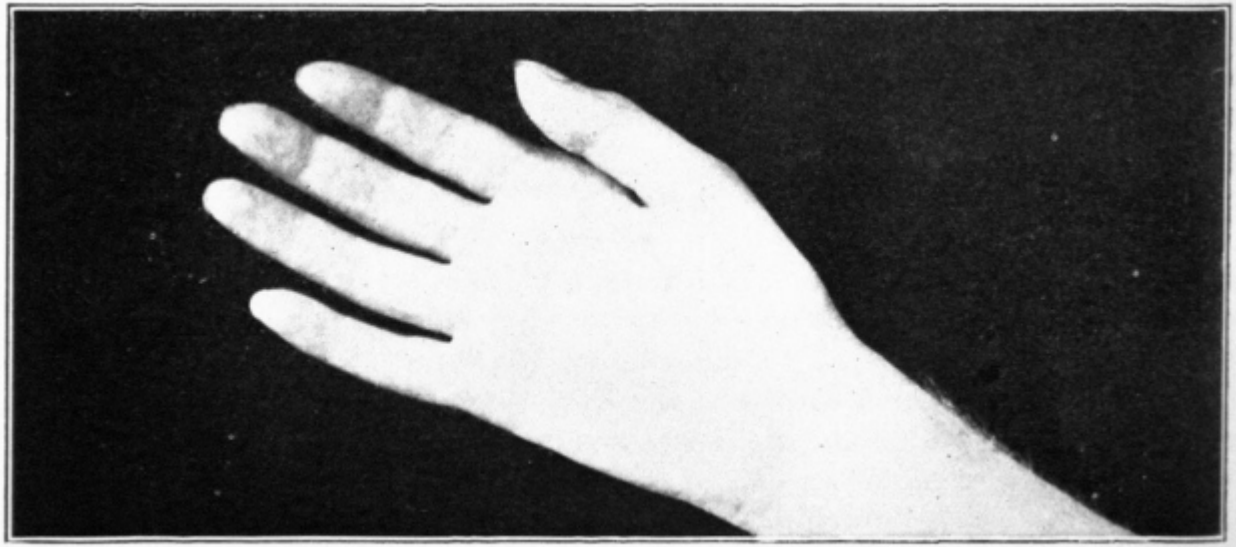

FIG. 118.—Brachial plexus lesion affecting common trunk of ulnar and median nerves