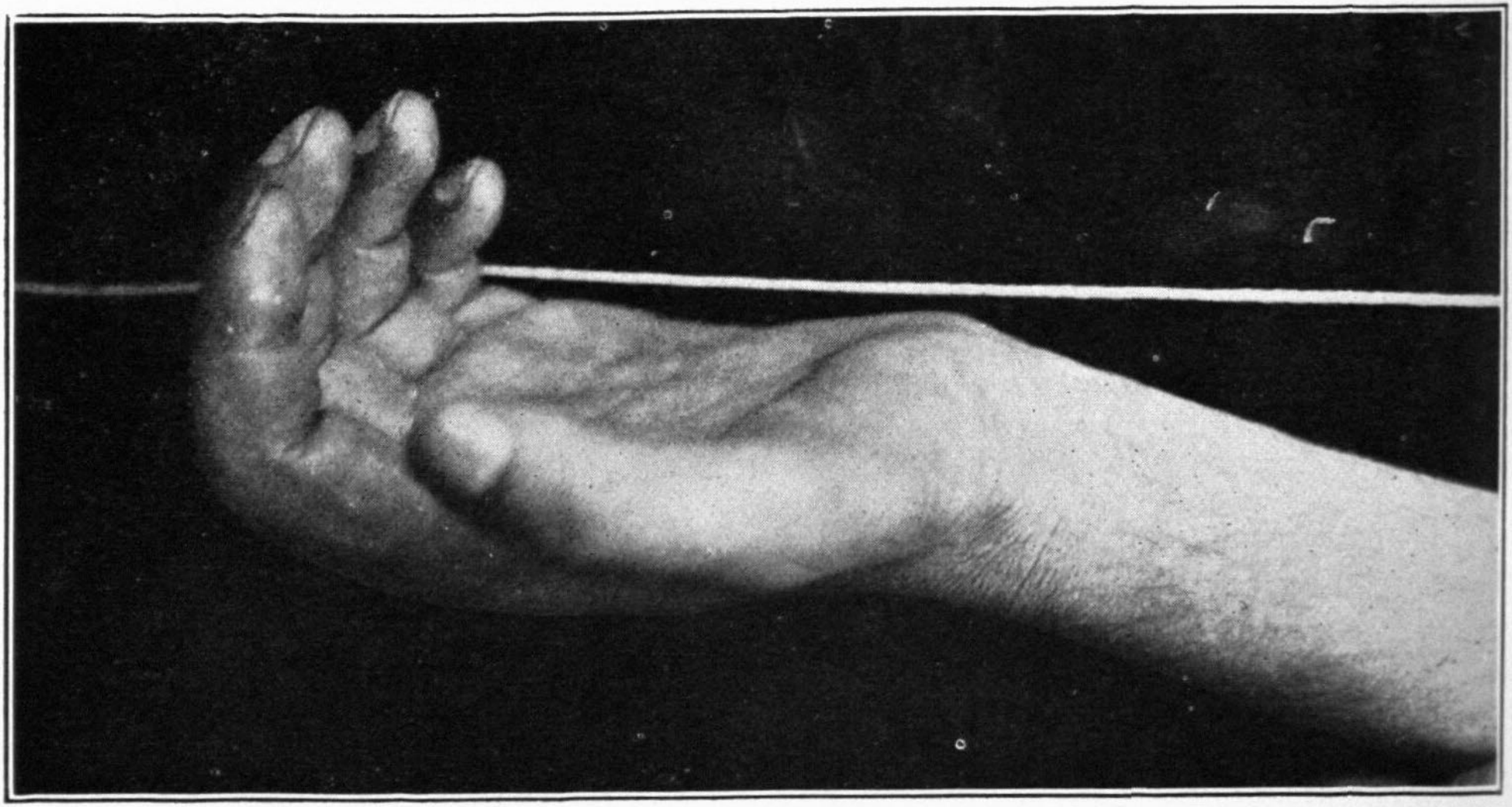

FIG. 113.—Flexion of the wrist by the extensor ossei metacarpi pollicis