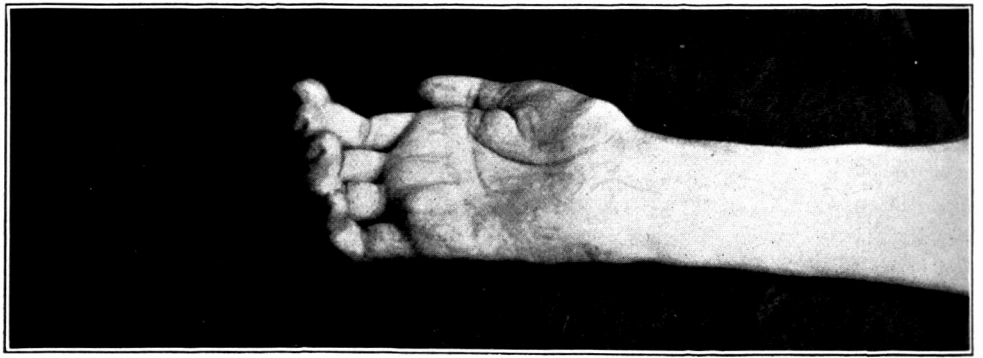

FIG. 112.—Ulnar and median nerve lesion