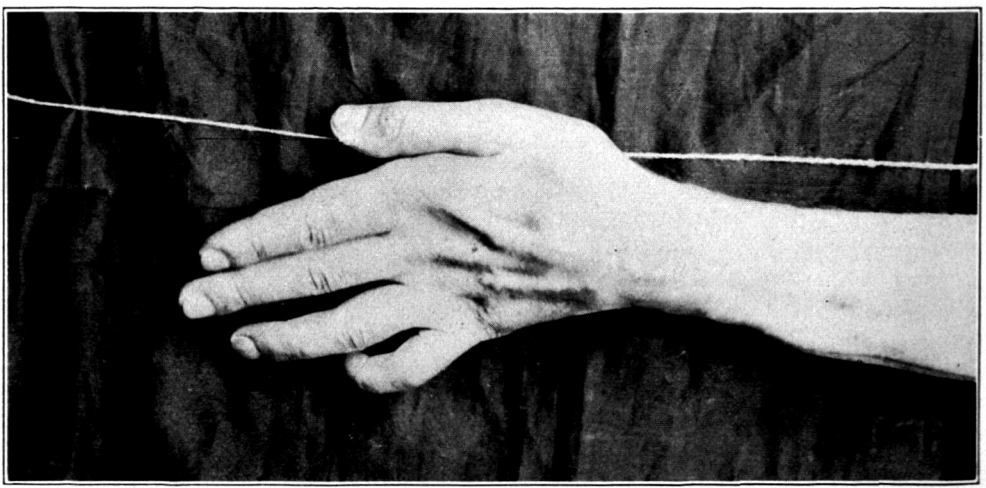

FIG. 110.—Adduction of index finger by extensor indicis with hand in ulnar deviation