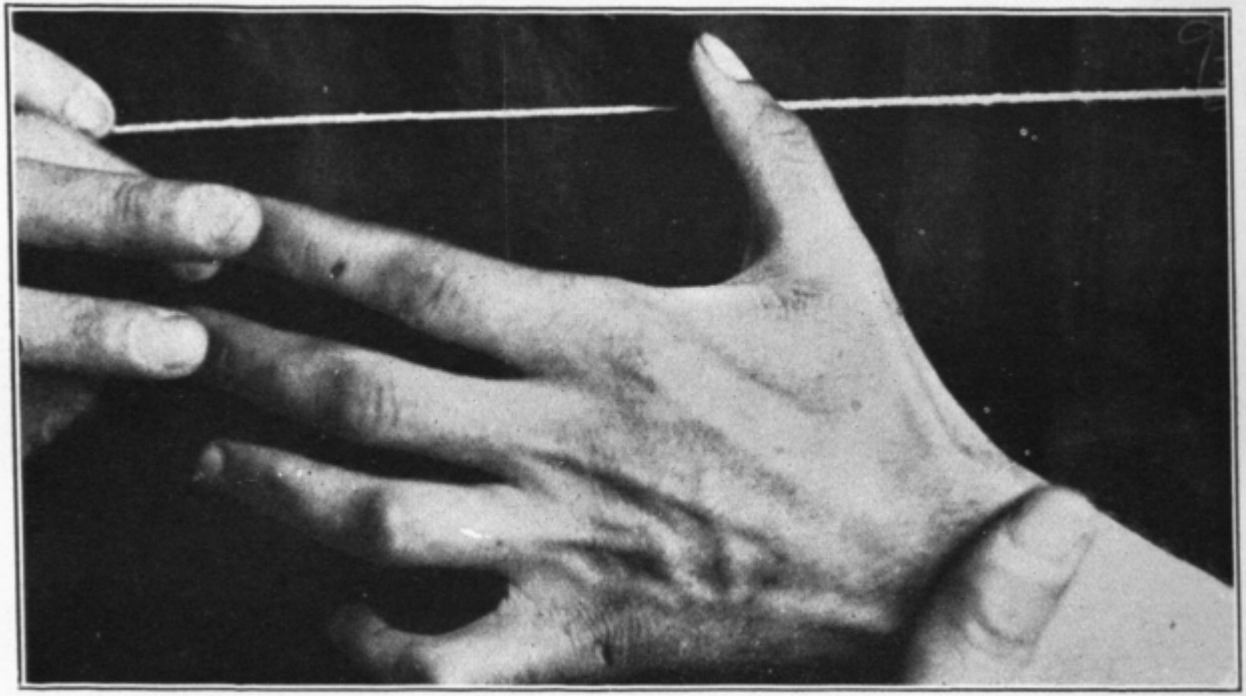

FIG. 107.—Extension of the distal phalanges of the index and middle fingers in ulnar palsy