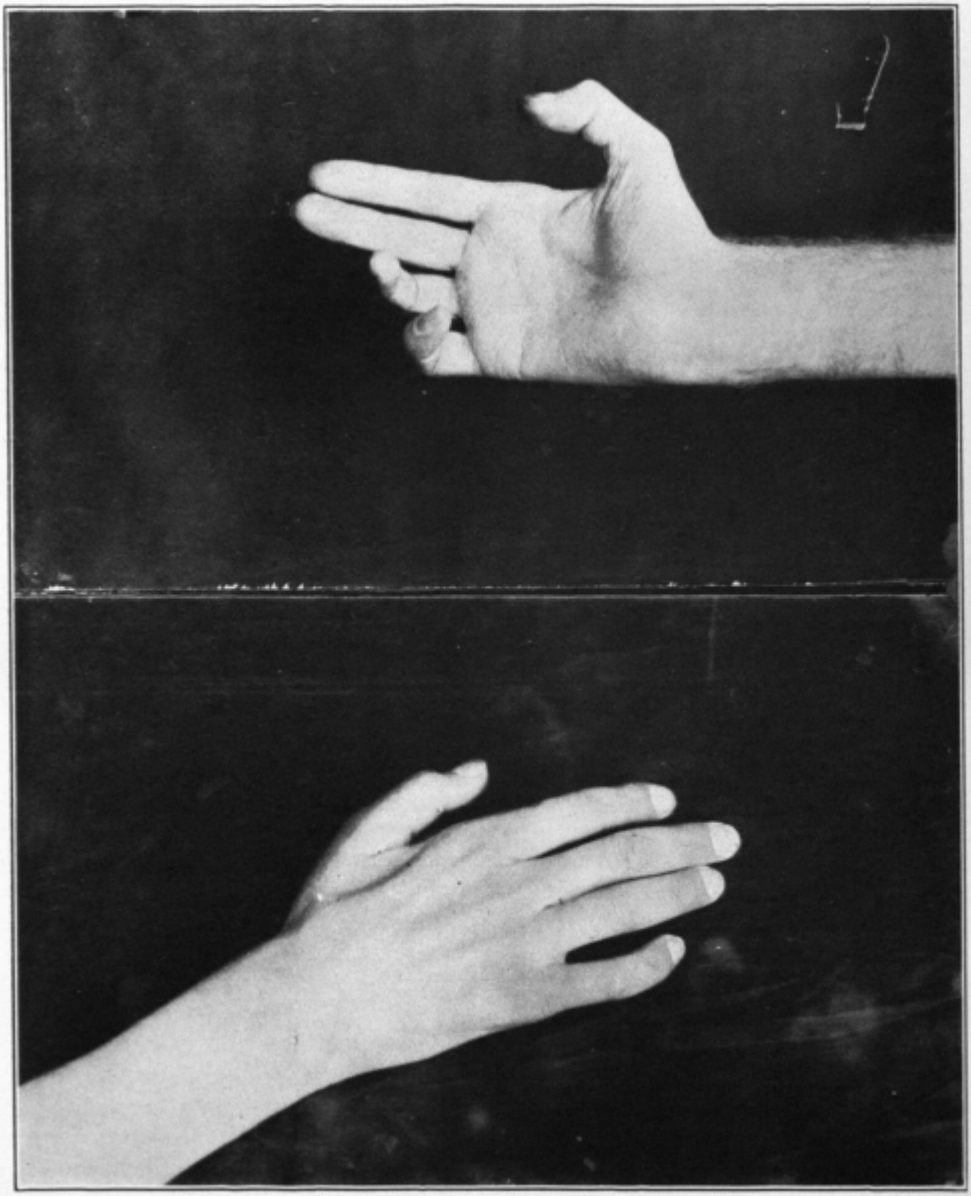

Fig. 105.—Ulnar nerve lesion