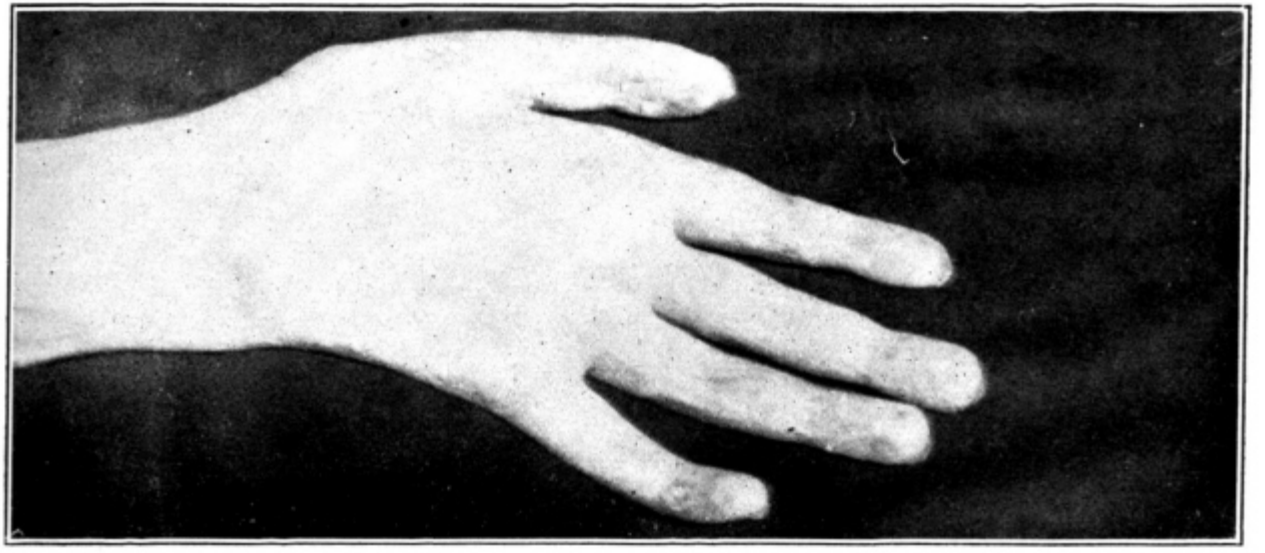

FIG. 104.—Causalgia in median nerve lesion combined with ulnar lesion