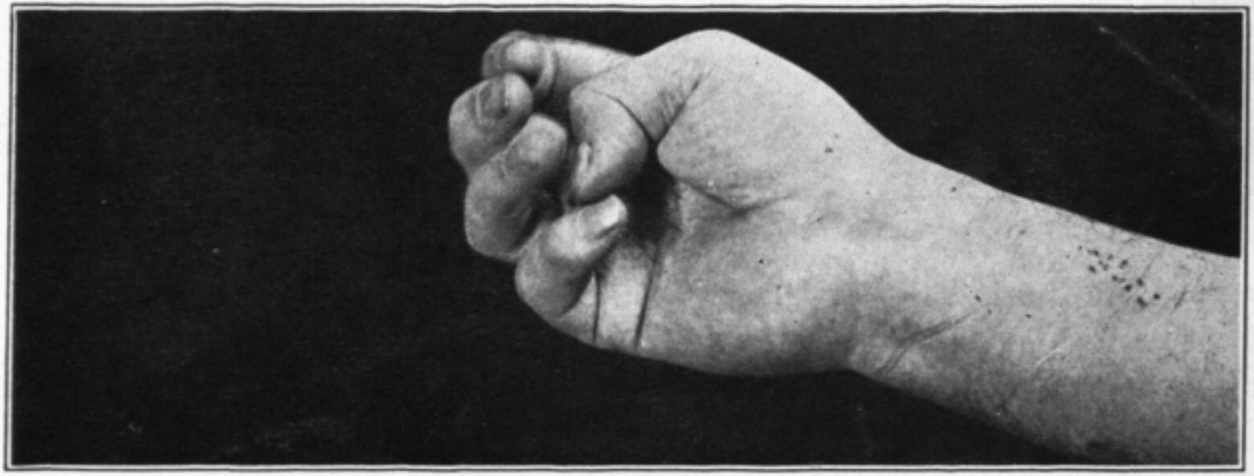

FIG. 101.—Opposition of the thumb by the adductor pollicis and flexor brevis pollicis in median nerve palsy