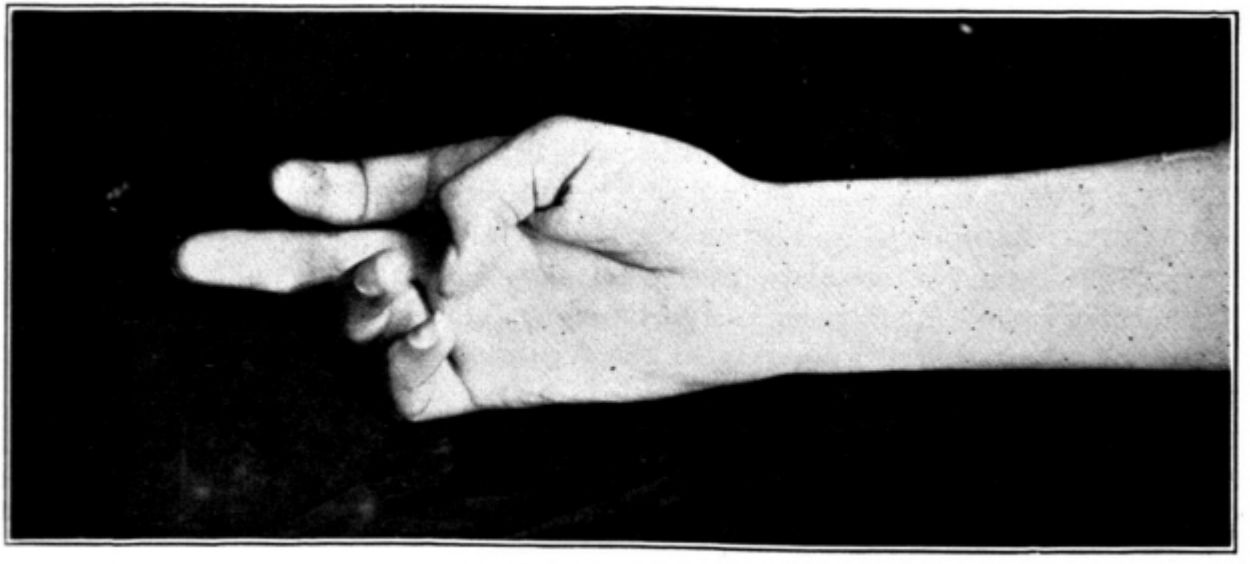

FIG. 100.—Imperfect opposition of thumb in median nerve palsy