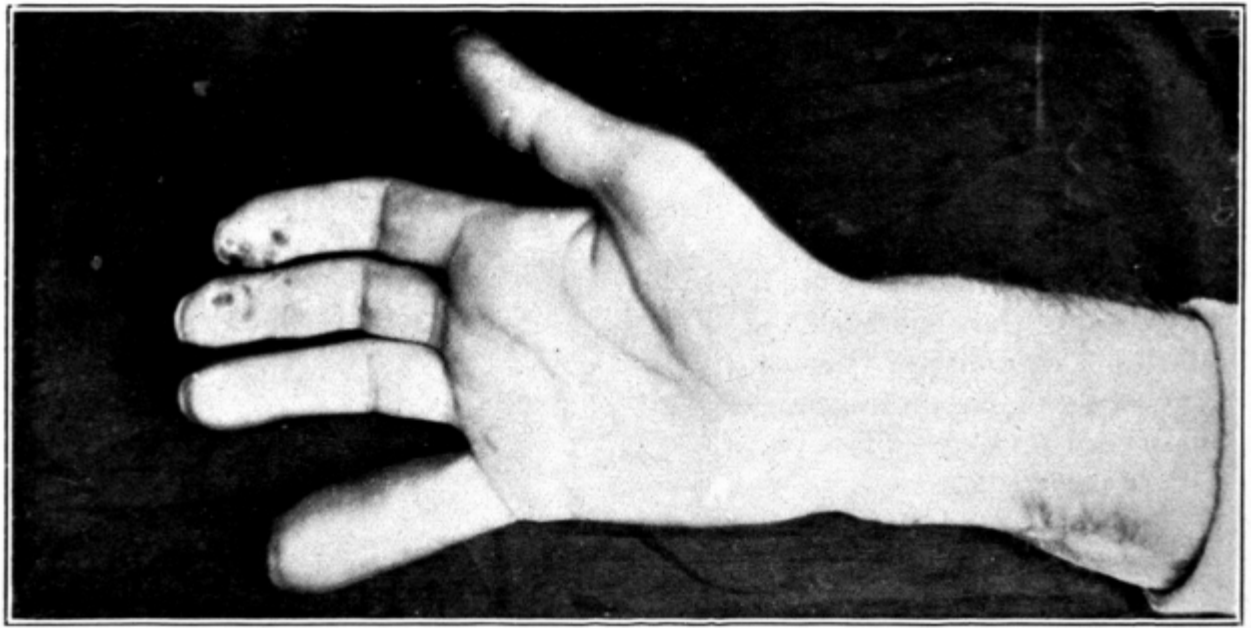

FIG. 97.—Median nerve palsy