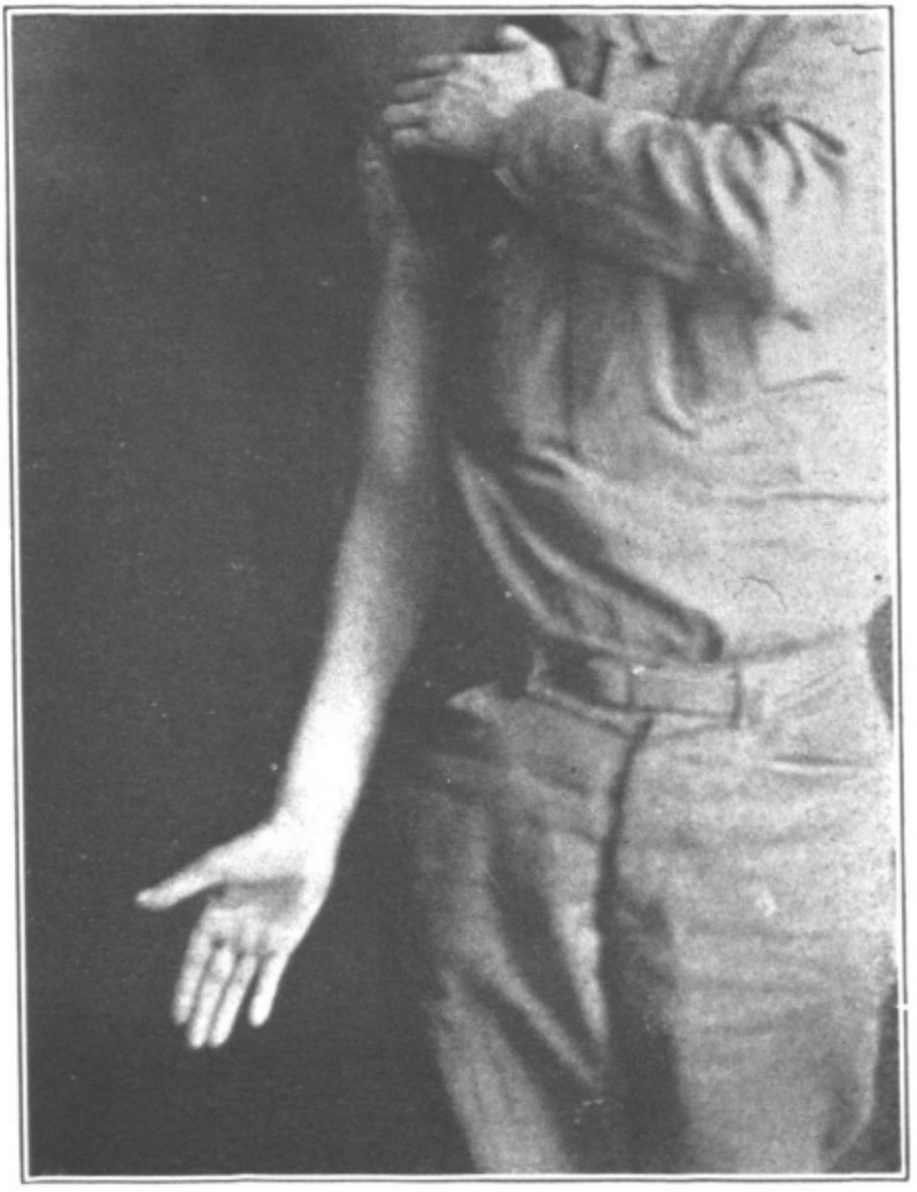

FIG. 96.—Sign of complete recovery of musculospiral nerve