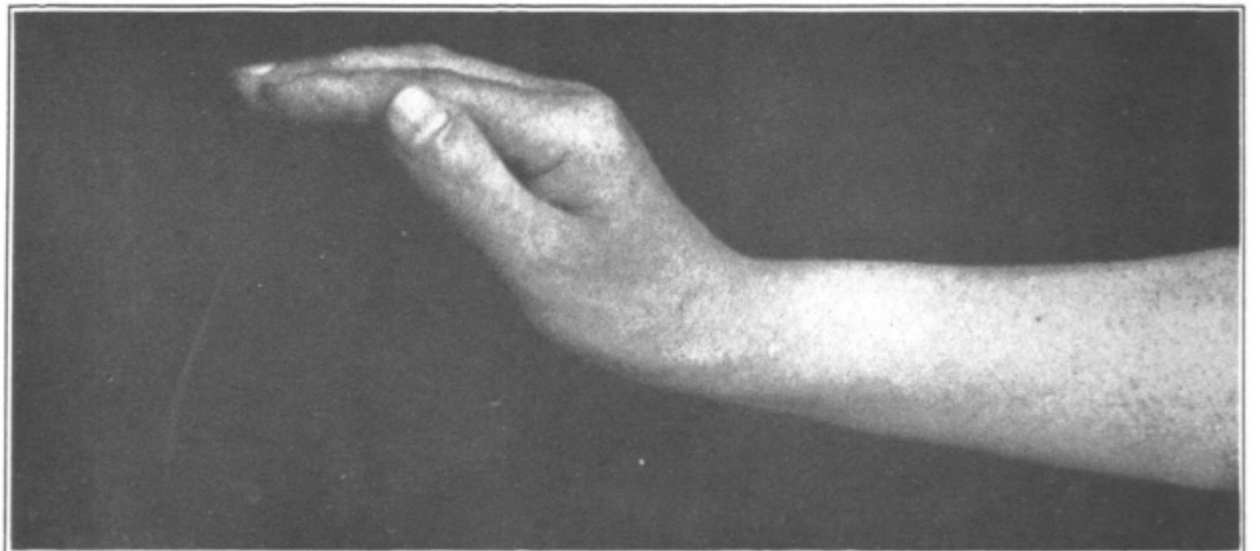

FIG. 95.—Partial lesion of musculospiral nerve