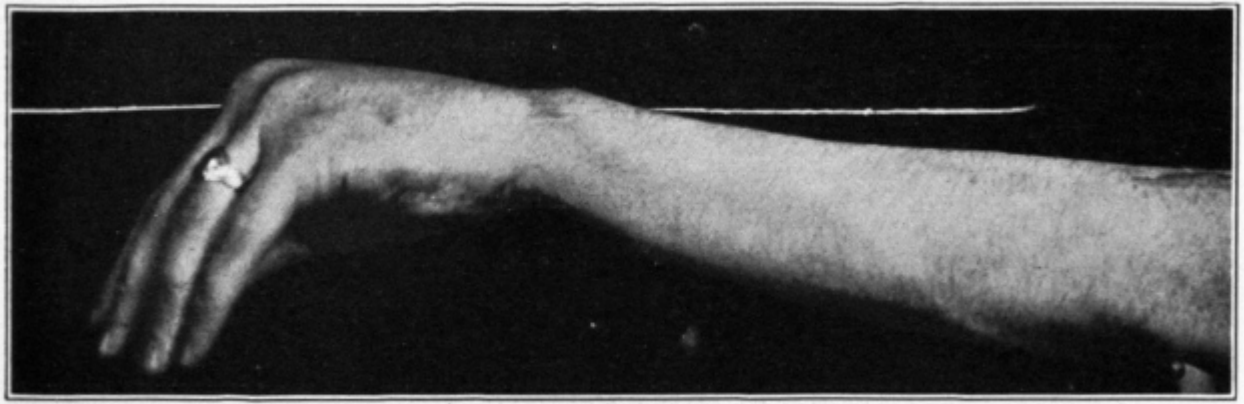

Fig. 93.—Extension of wrist by supplementary movement of contraction of pronator radii teres