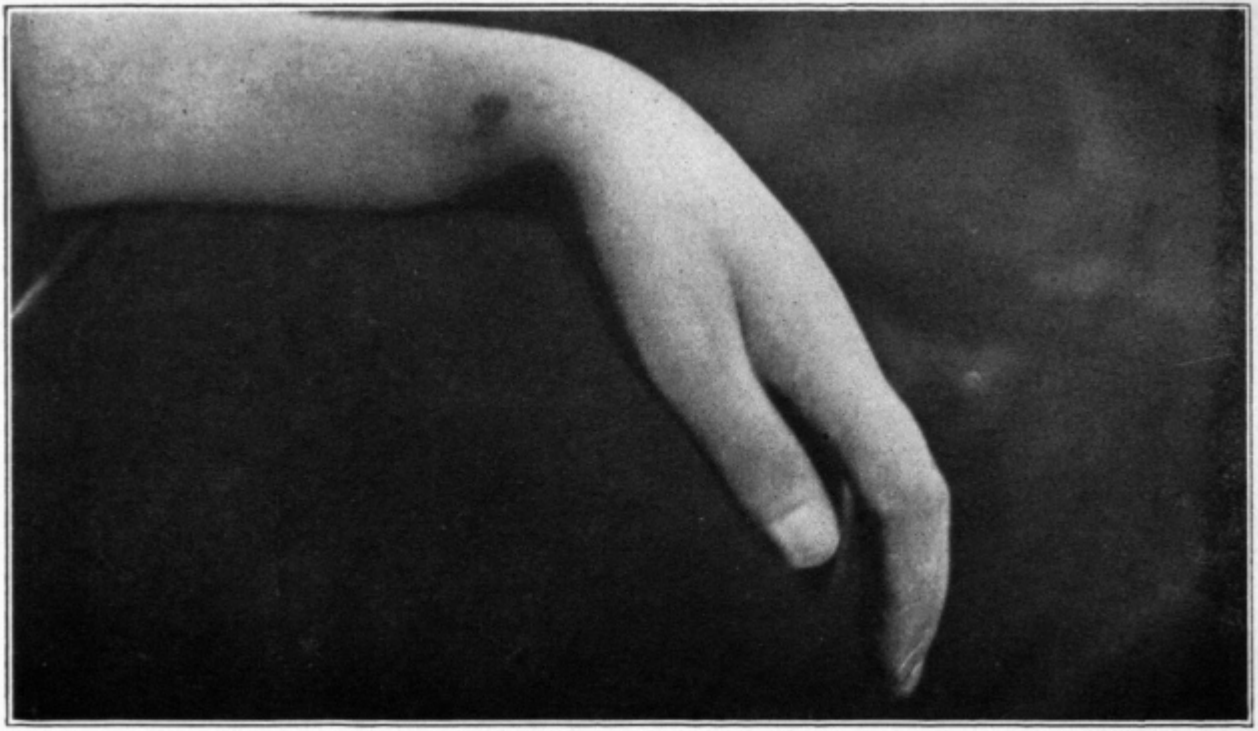

Fig. 90.—Musculospiral palsy