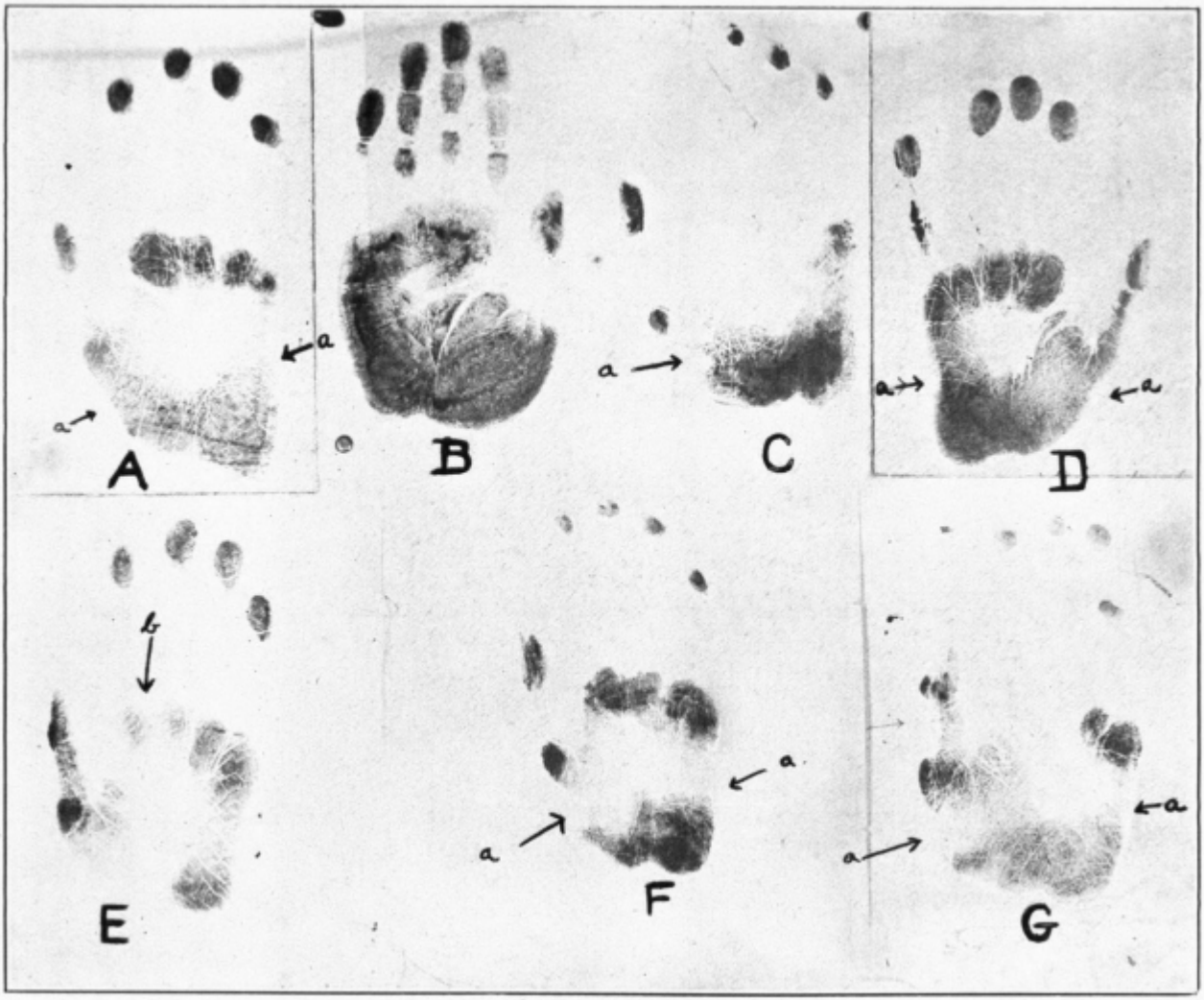

FIG. 89.—Imprint in combined lesions of ulnar and median nerves: *a*, Atrophy of thenar and hypothenare minences; *b*, separation of mounds