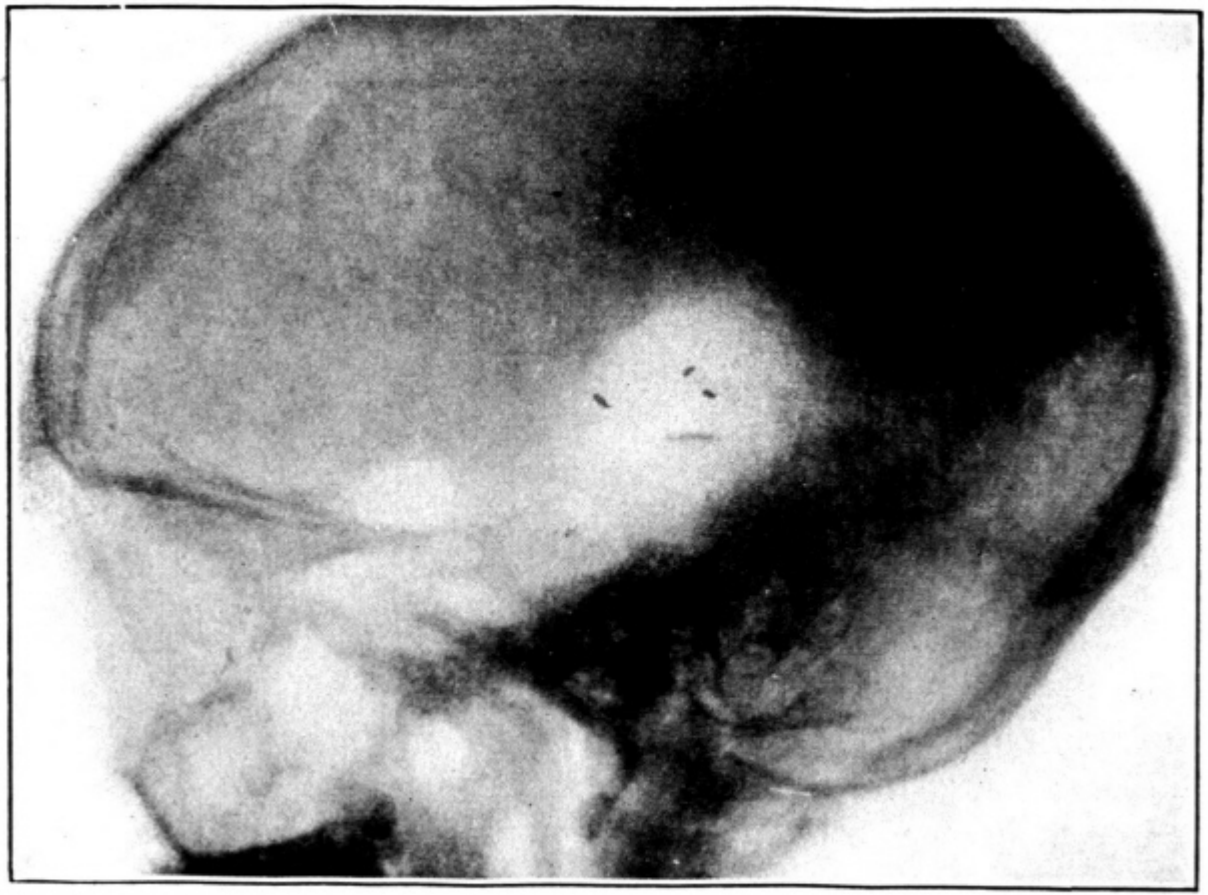

FIG. 79.—One minute bone fragment and three silver clips applied at operation overseas for control of hemorrhage