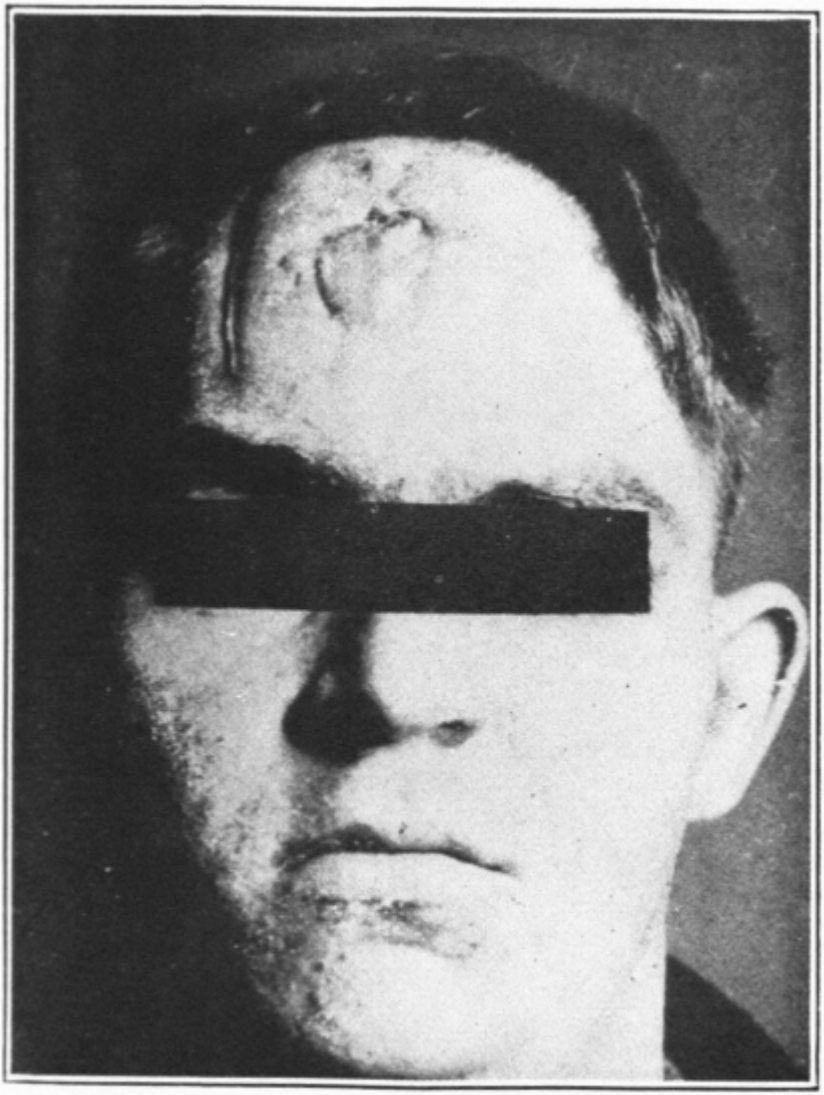

FIG. 70.—Patient with hernia at the site of the frontal defect. NOTE.—This photograph refers to autopsy specimen (fig. 71)