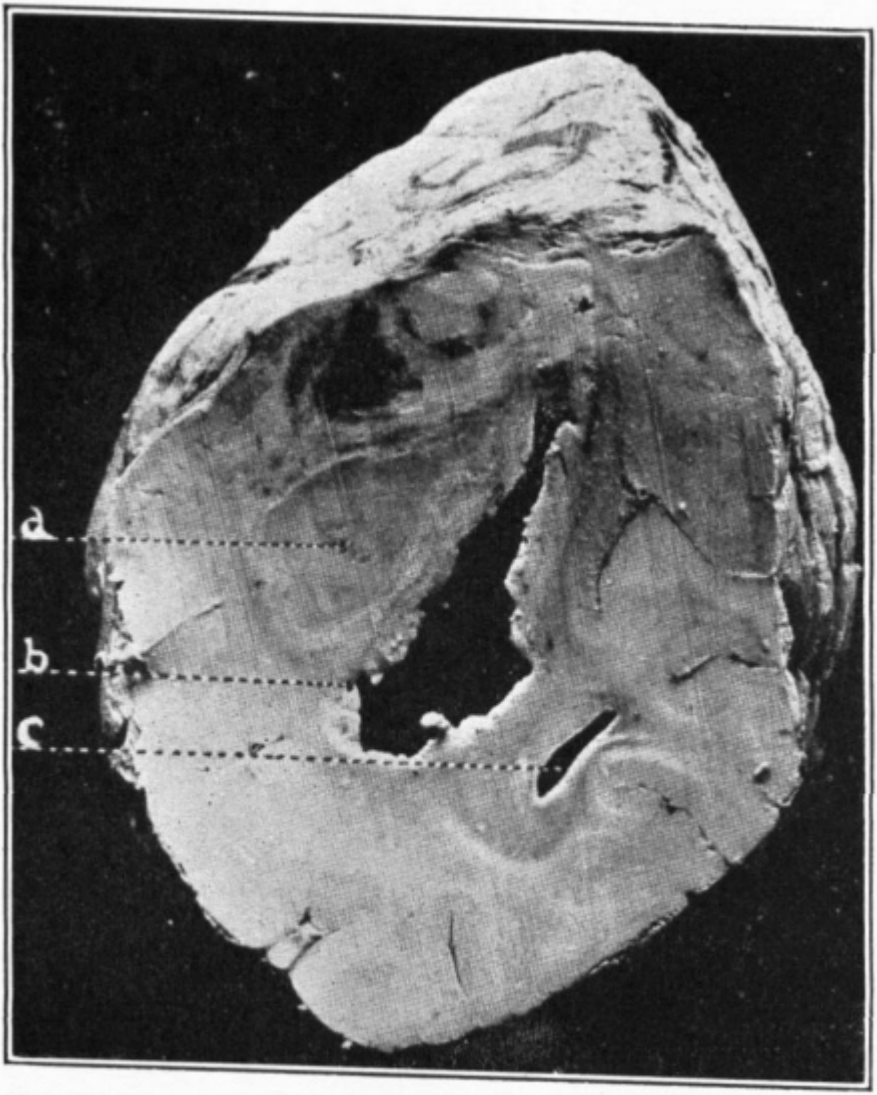

FIG. 67.—D. F. A transverse section through occipital pole of brain. *a*, Primary abscess with firm wall; *b*, secondary abscess cavity; *c*, occipital pole of lateral ventricle