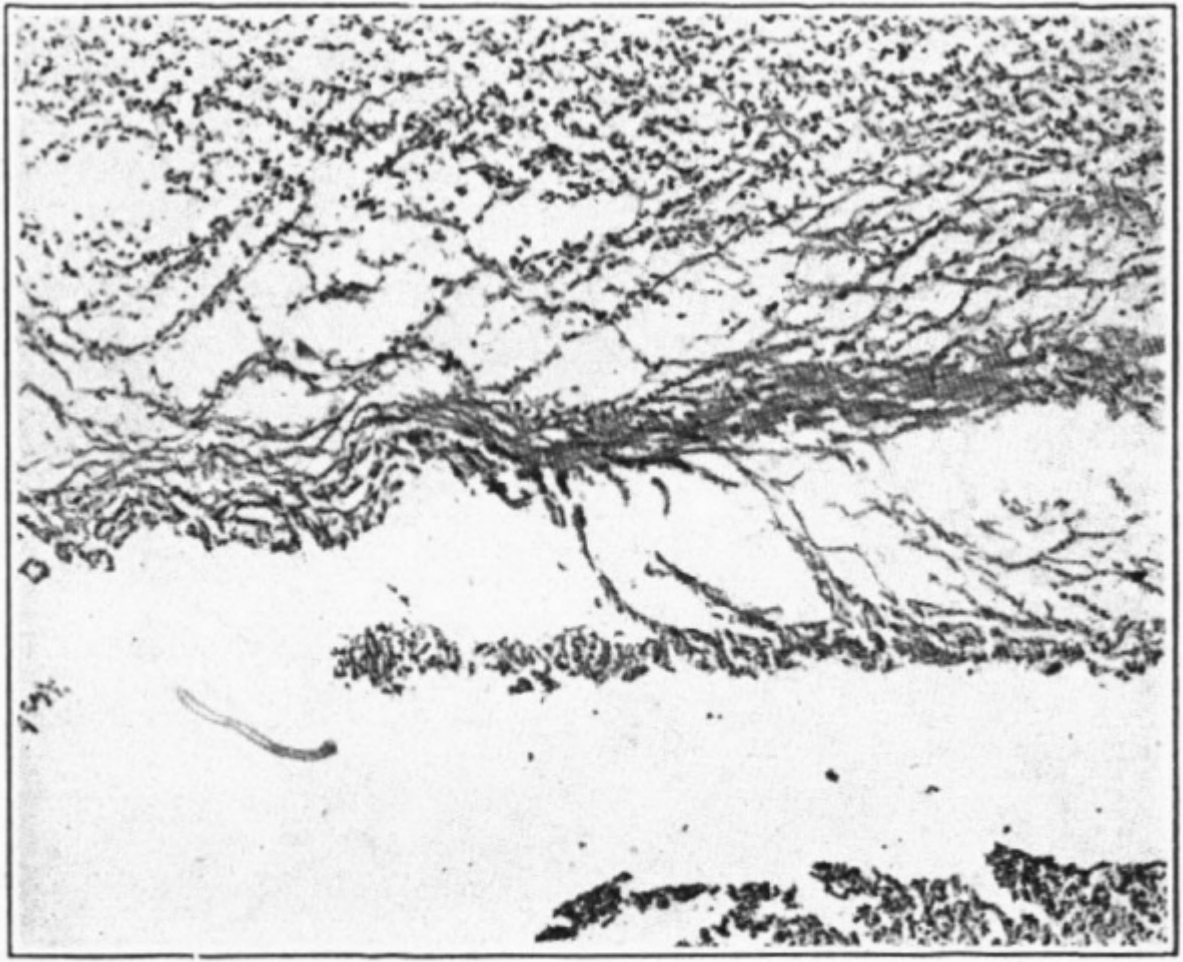

FIG. 62.—L. F. Section of the innermost portion of abscess wall in Figure 60. Because of the necrosis the cellular elements have fallen out, leaving the delicate fibers in plain view. ×85