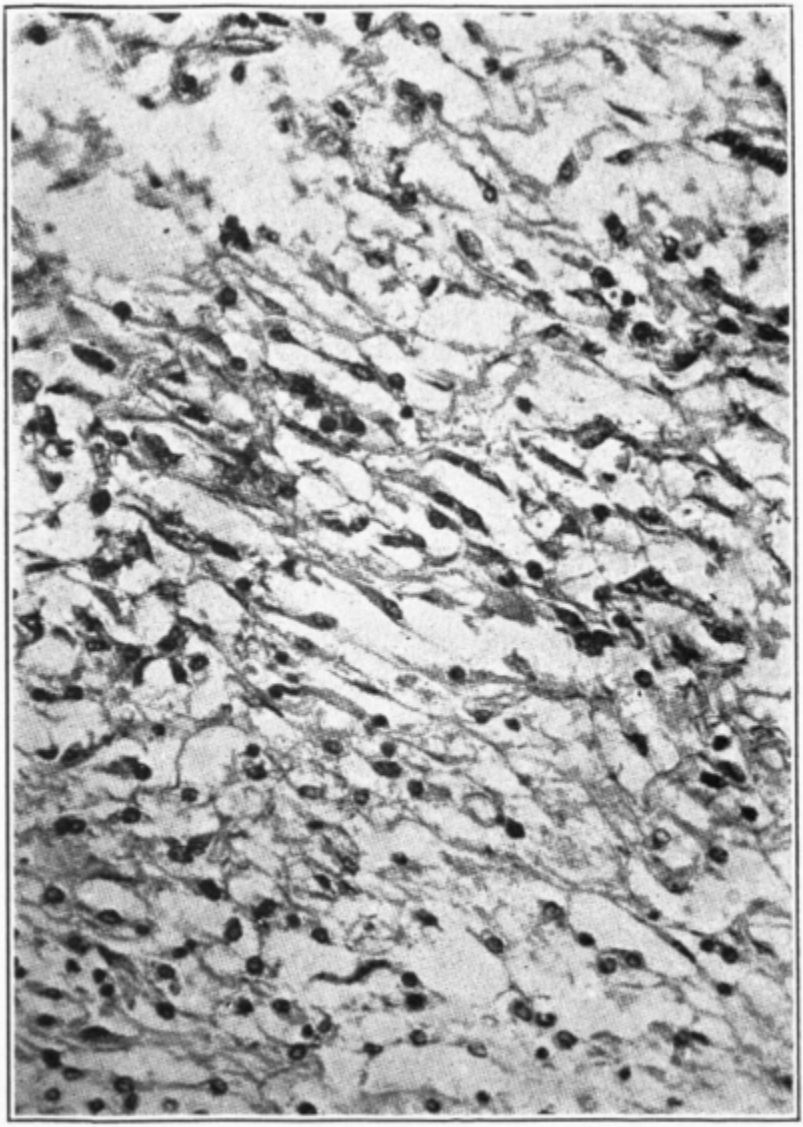

FIG. 61.—L. F. A higher magnification of wall of abscess seen in Figure 60, showing the membrane to consist of delicate fibrils. ×325