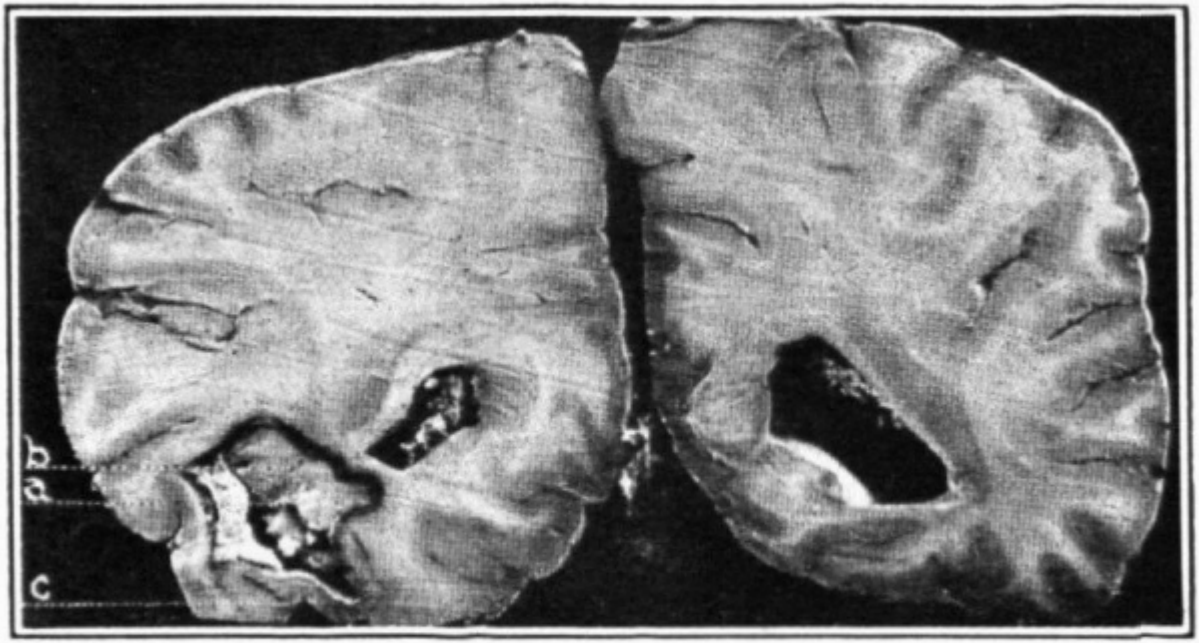

FIG. 55.—Frontal section of a brain with left temporal lobe abscess. *a*, Abscess cavity; *b*, abscess wall and site of section shown in Figure 56; *c*, site of section shown in Figure 57