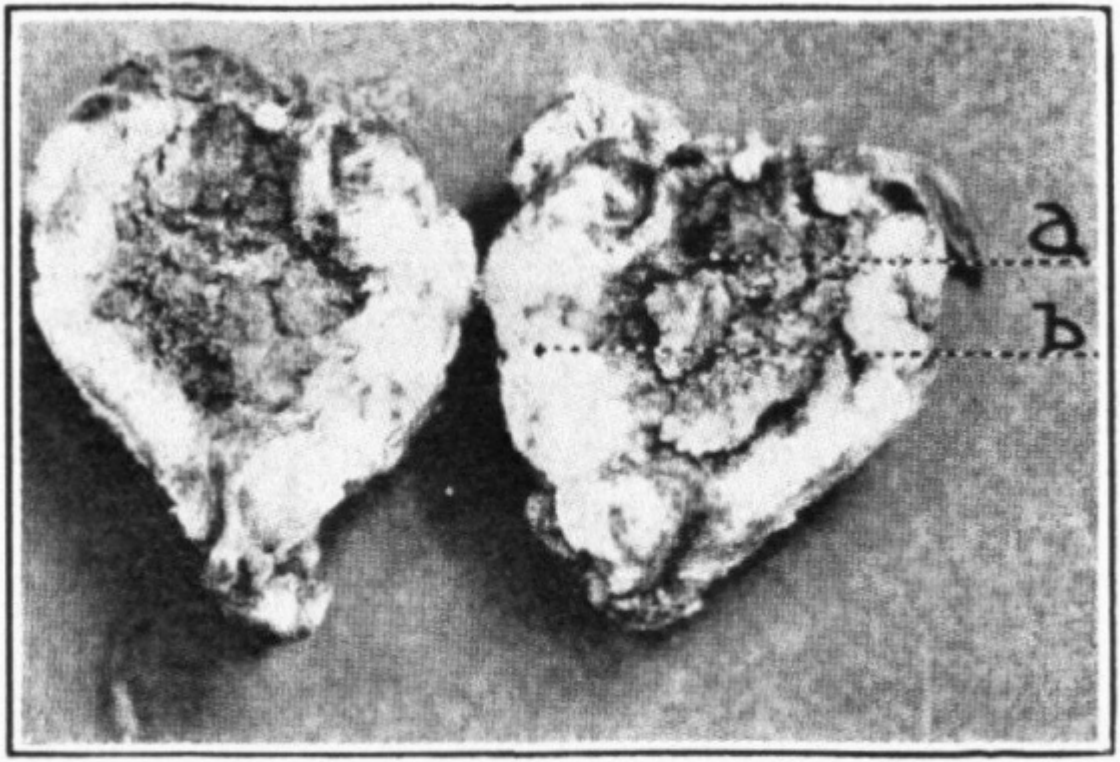

FIG. 47.—Cranial abscess. *a*, Bone fragments at center of abscess; *b*, fibrous tissue abscess wall and site of section shown in Figure 48