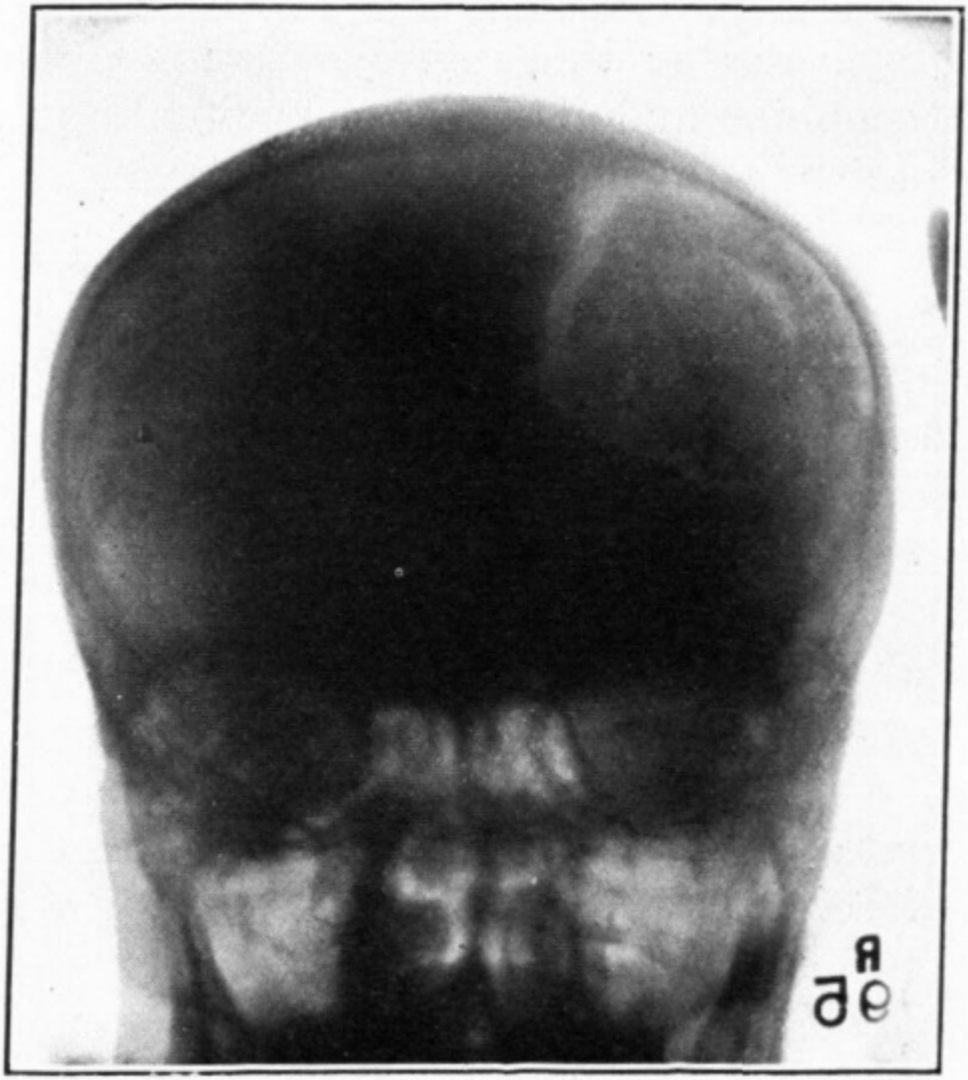

FIG. 46.—Roentgenogram showing osteomyelitis of osteoplastic flap and outline of bony defect