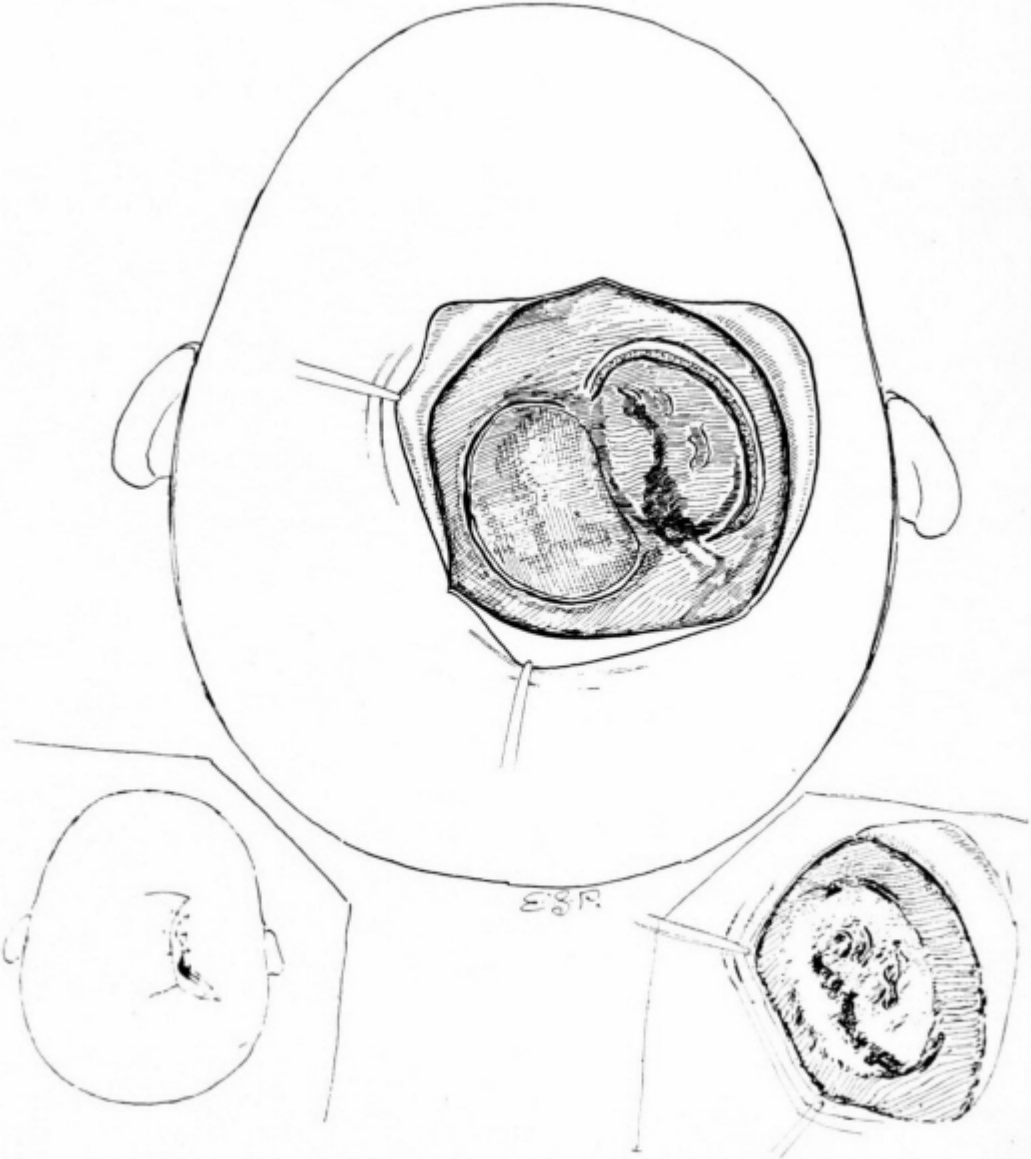

FIG. 42.—This and Figure 43 illustrate Bagley's hinged flap method. The scar has been excised, the flap reflected, and the graft outlined on the skull adjacent to the defect