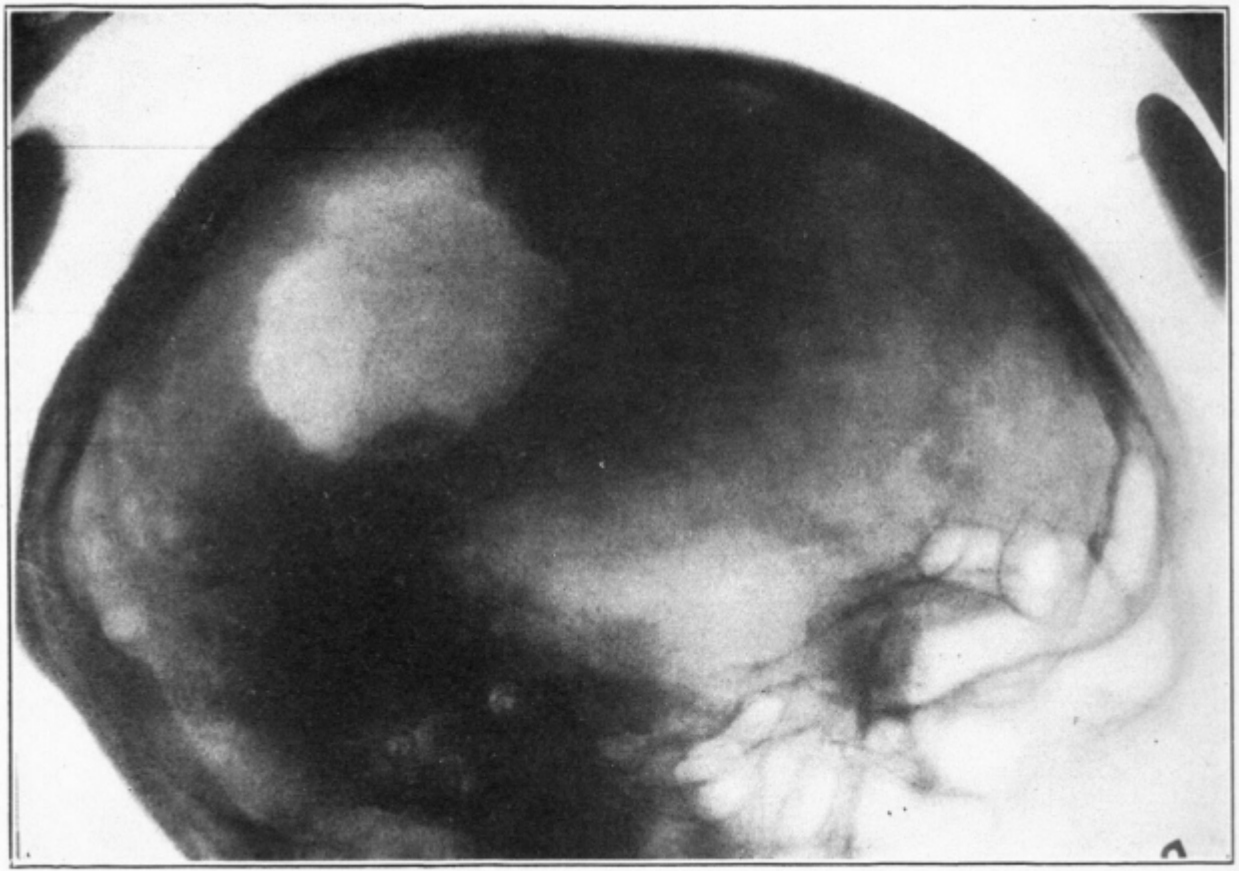

FIG. 39.—Posterium parietal defect. Roentgenogram before cranioplasty