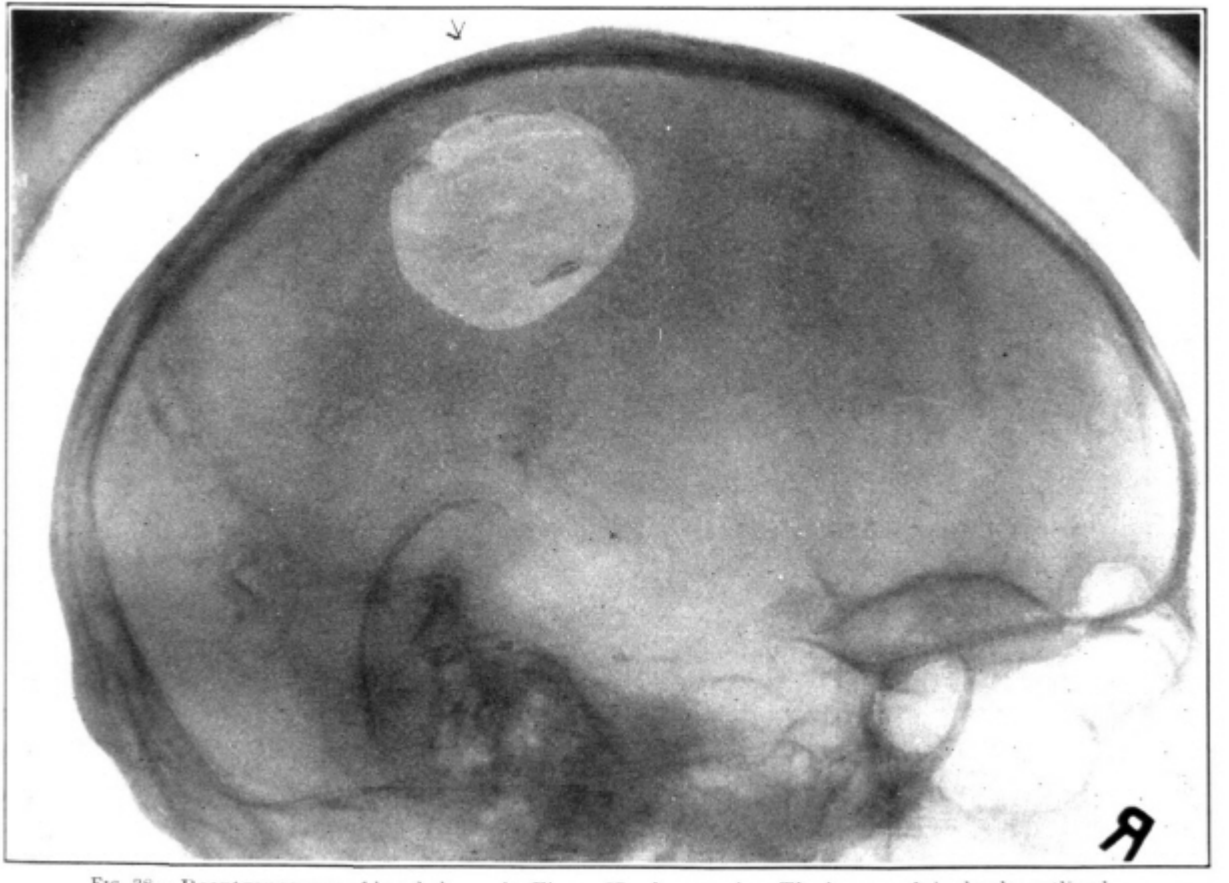

FIG. 38.—Roentgenogram of head shown in Figure 37, after repair. The bone graft is clearly outlined