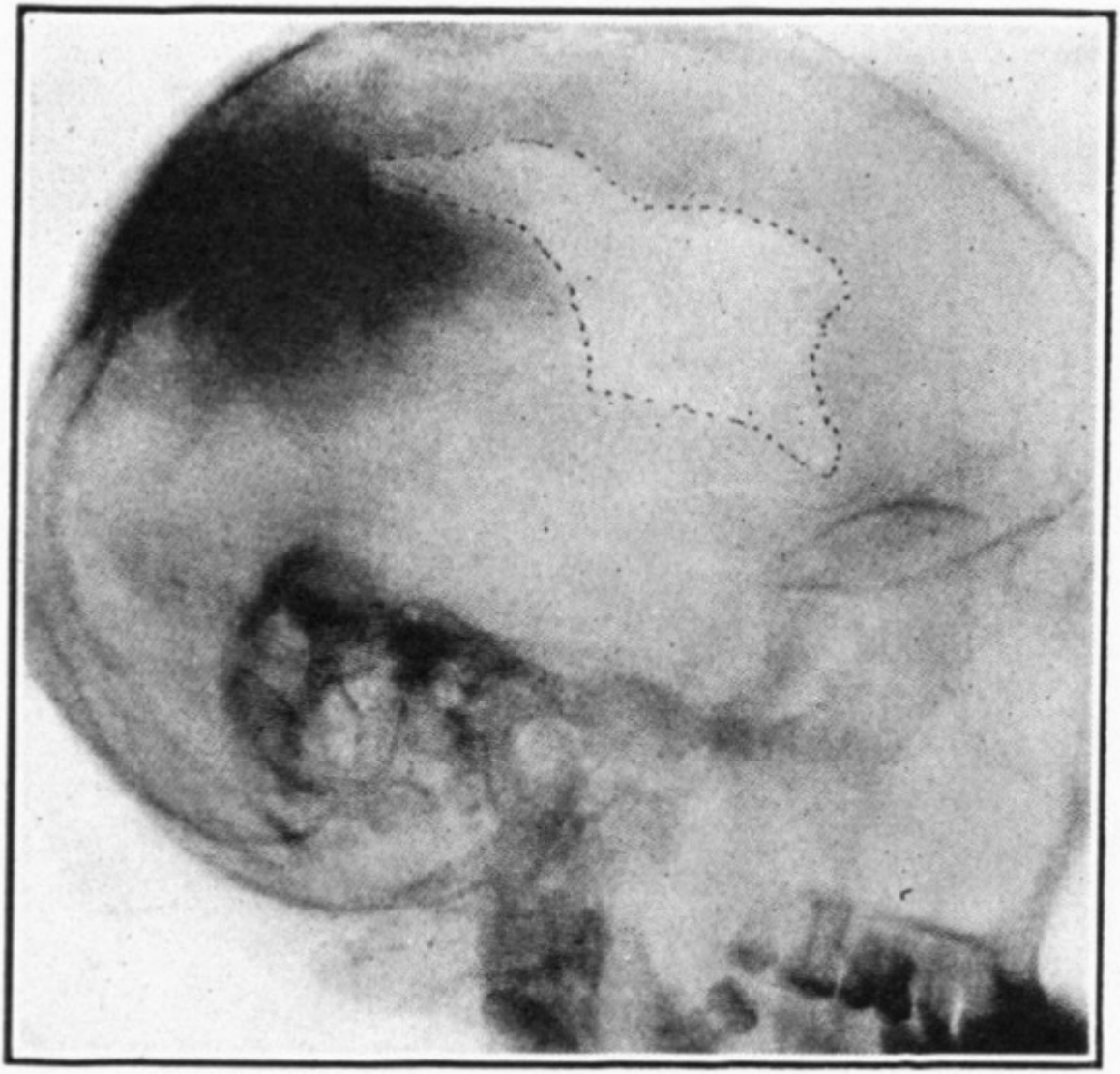

FIG. 34 —Skiagraph of an irregular defect in the parietal region