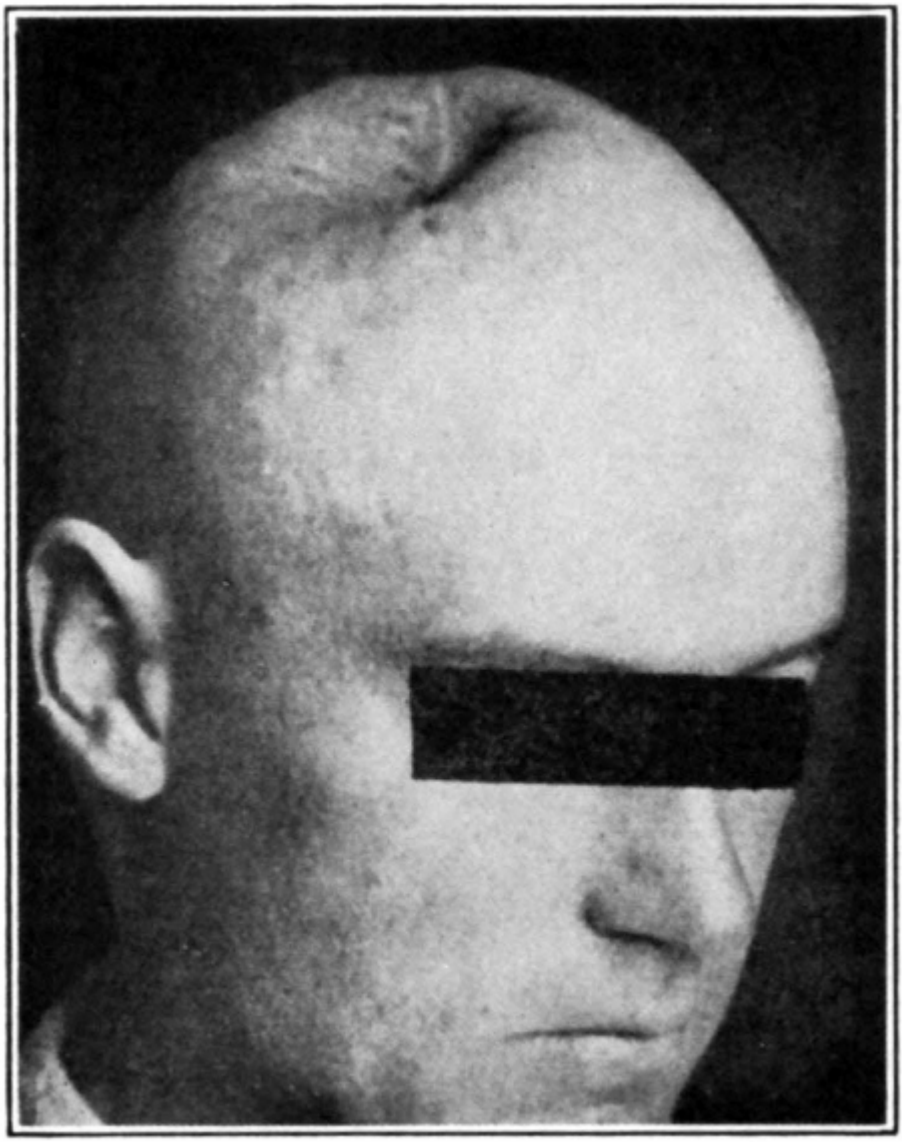

FIG. 32.—Characteristic defect in the parietal region