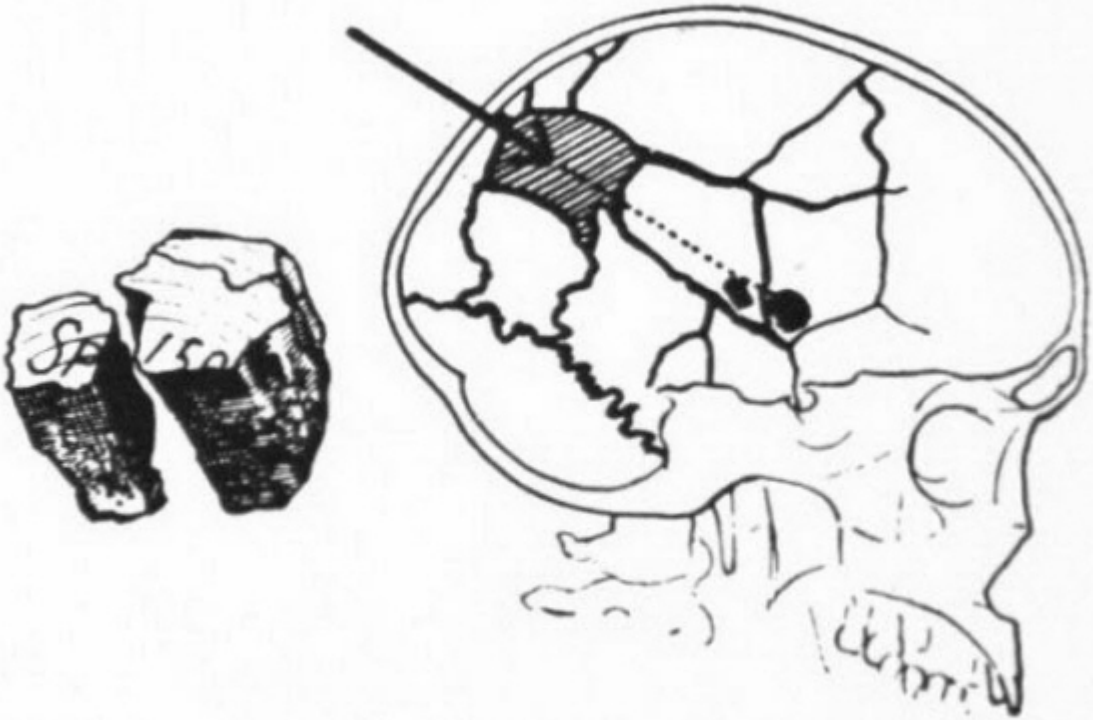

FIG. 26.—Split shell fragments in temporal lobe. (Cushing)