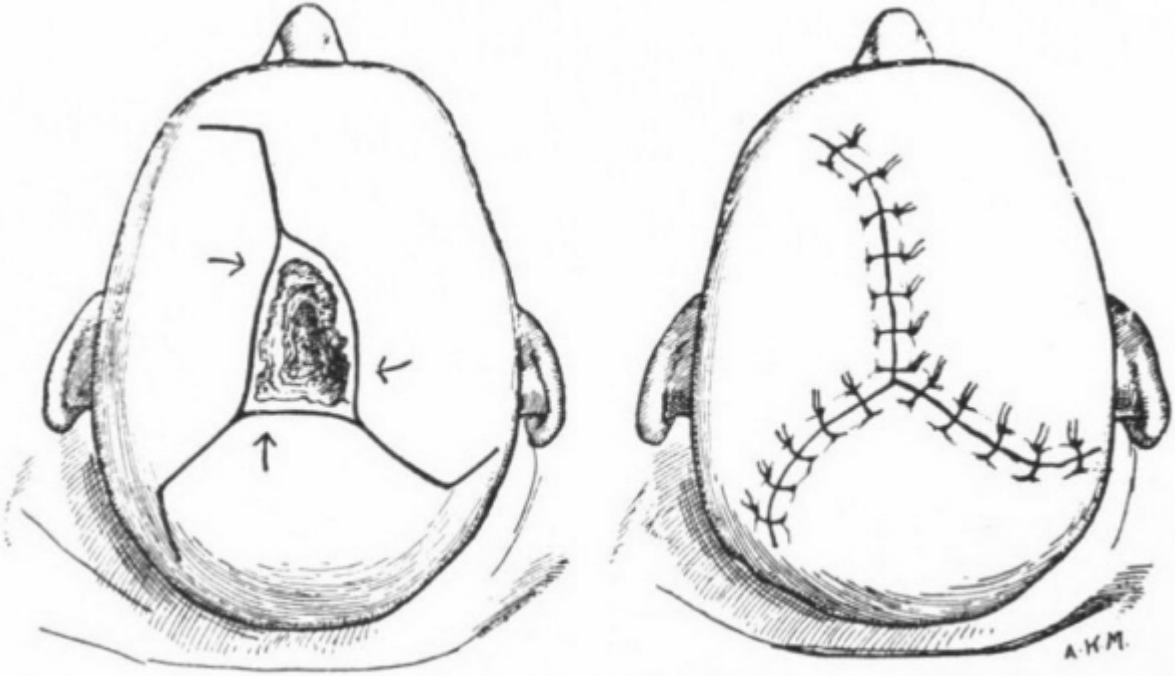

FIG. 22.—Three-legged (Isle of Man) incision for larger wound of cranial vault. (Cushing)