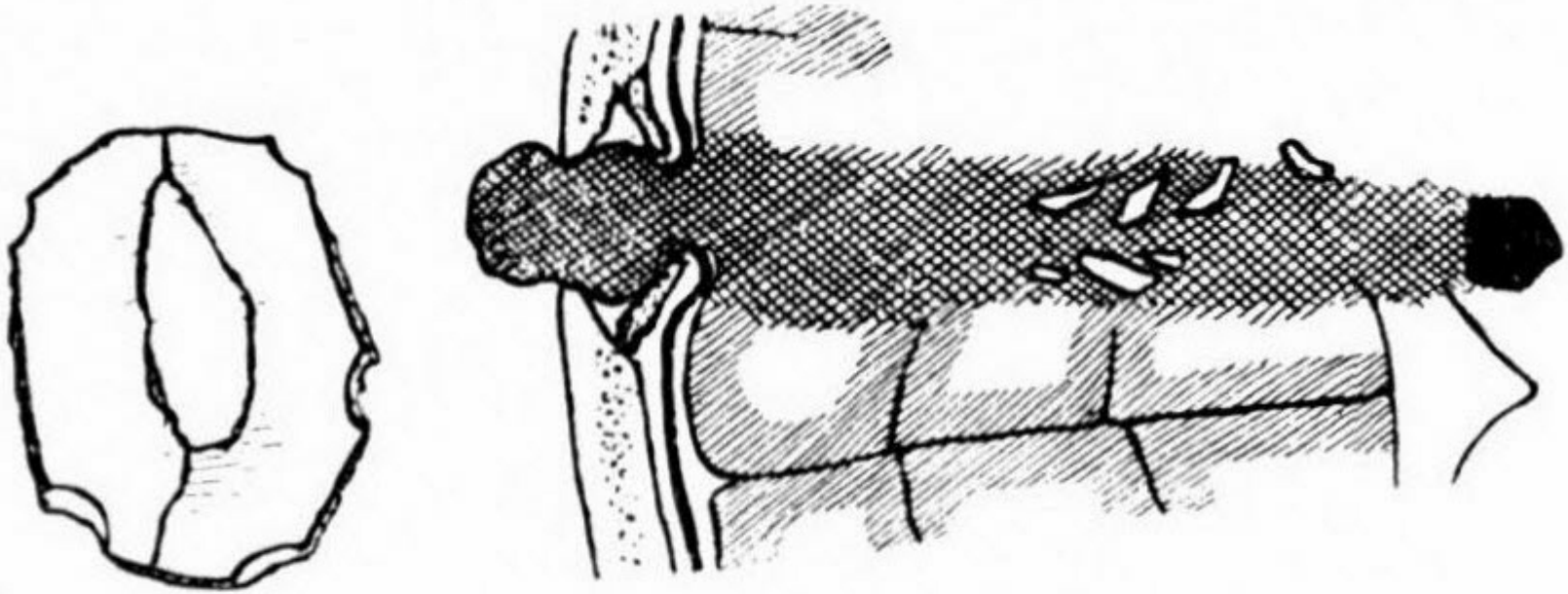

FIG. 10.—Grade VI: Wounds with ventricles penetrated or traversed (*a*) by bone fragments, (*b*) by projectile