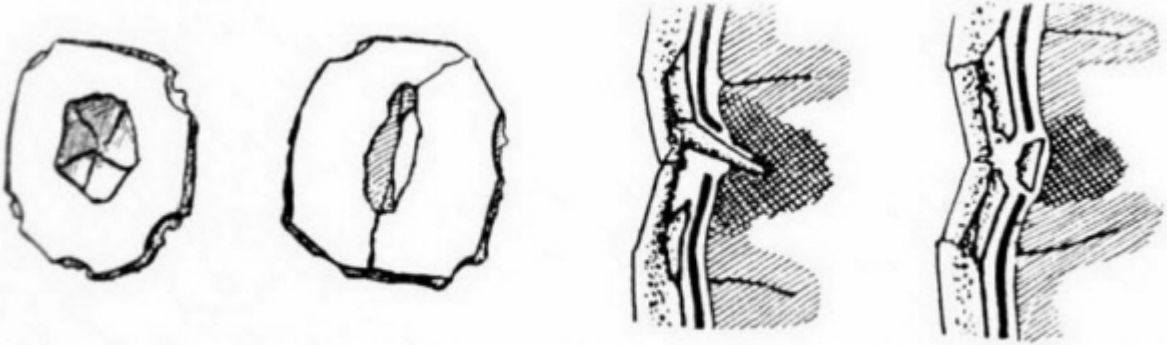

FIG. 7.—Grade III: Local depressed fractures of various types, with the dura punctured