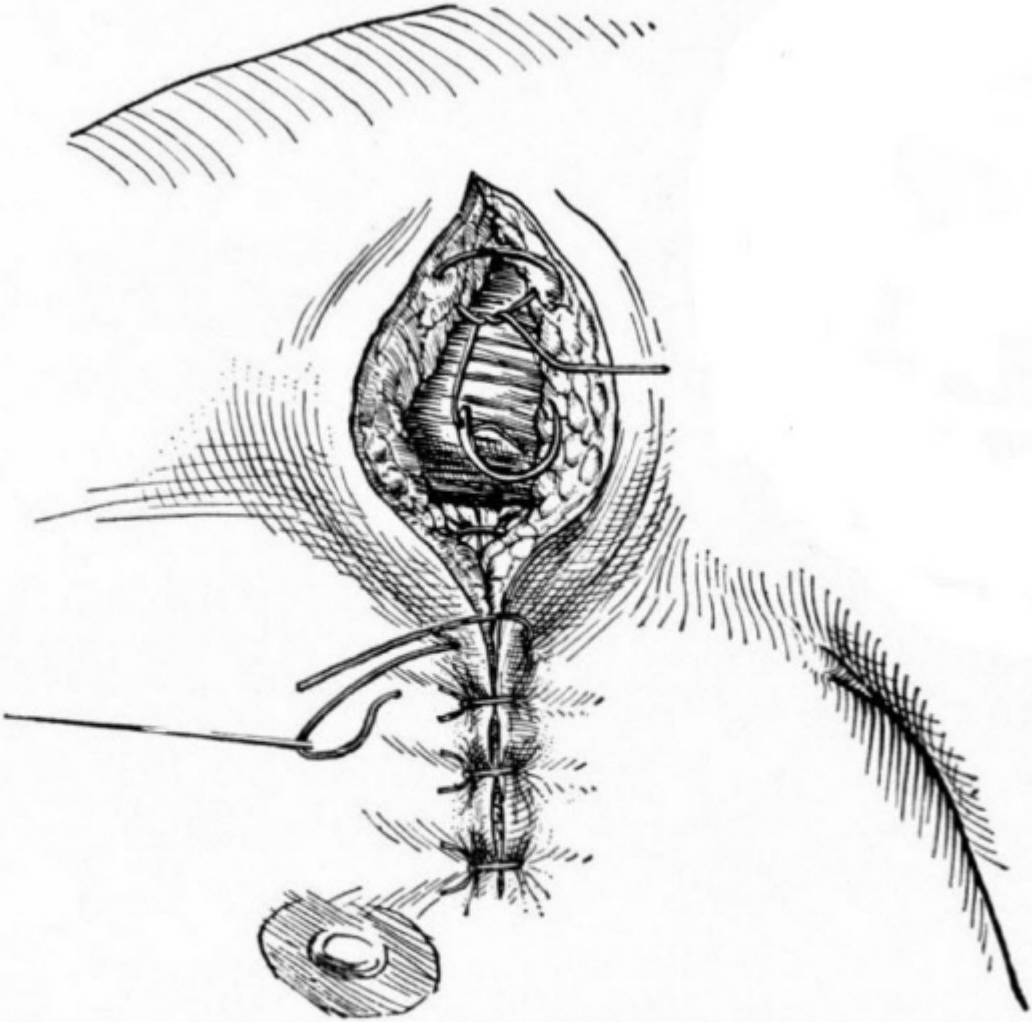

FIG. 200.—Closure of the chest wall after thoracotomy. The deep layer of the superficial fascia is closed with buried sutures