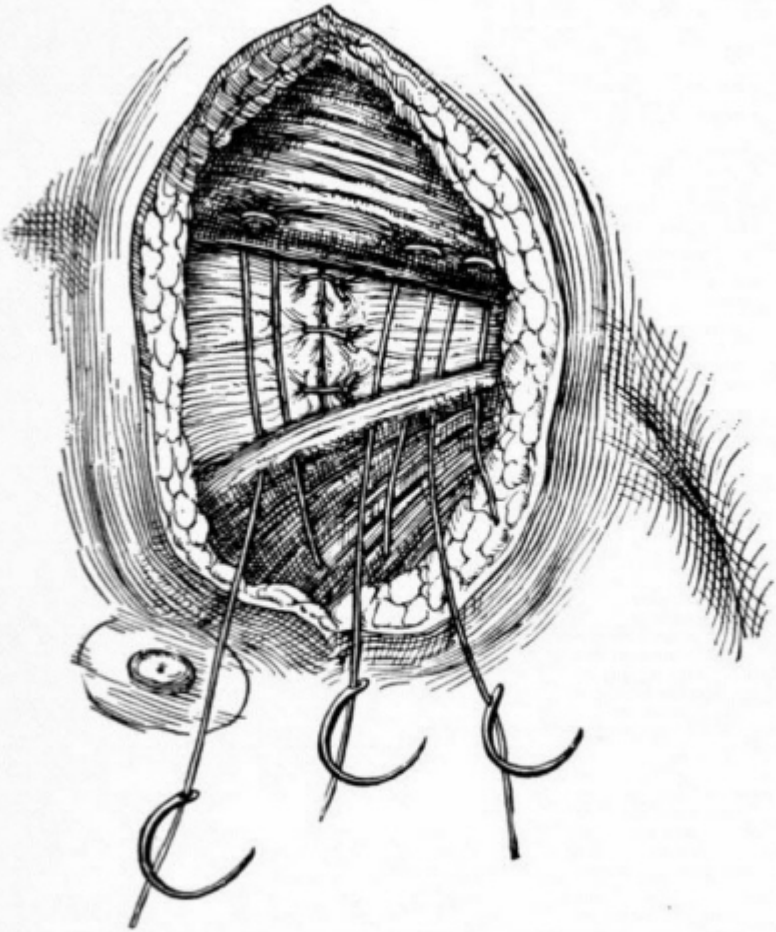

FIG. 199.—Closure of the chest wall after thoracotomy. The margins of the pectoralis major and latissimus dorsi are united with mattress sutures to protect the deep wound