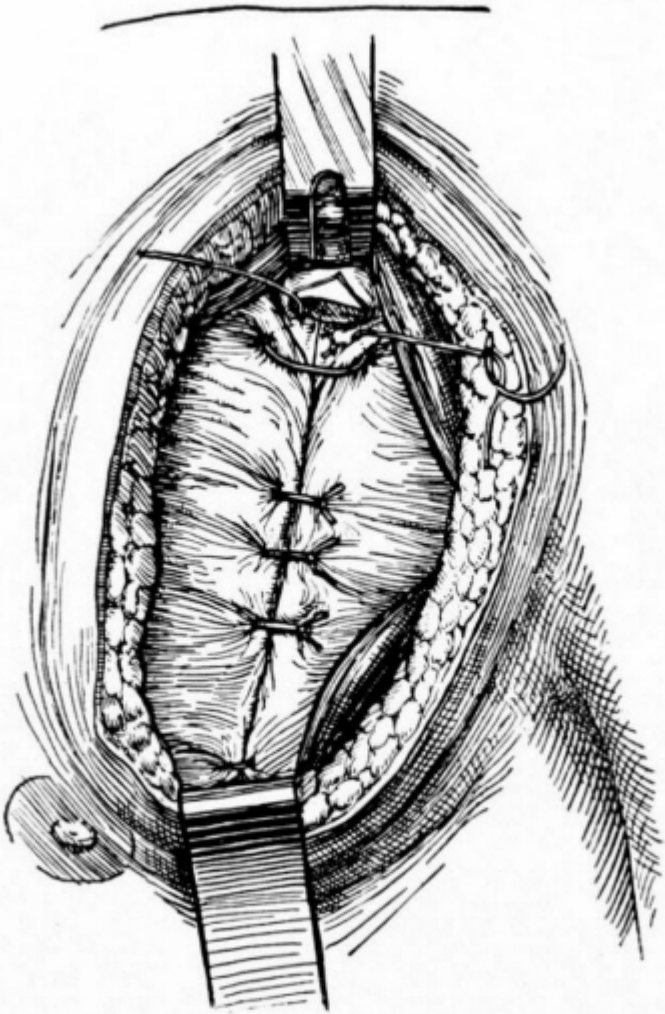

FIG. 198.—Closure of the chest wall after thoracotomy. The layer of fat and muscle is closed over the defect caused by rib resection