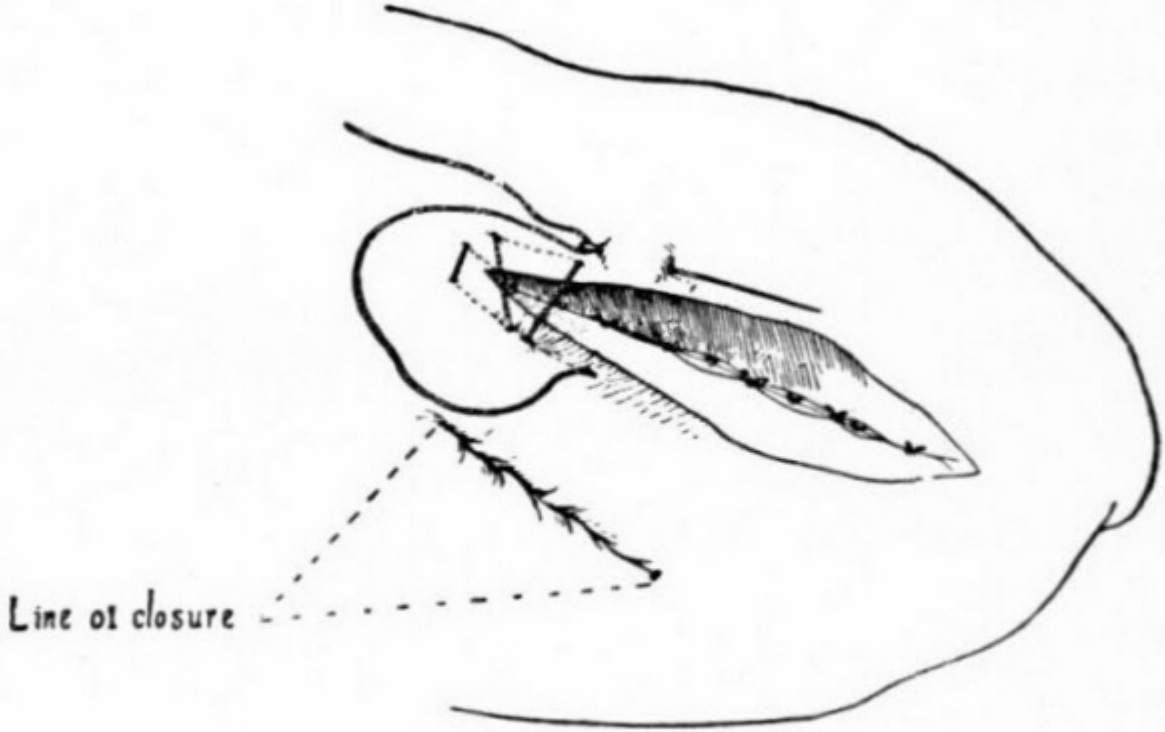

FIG. 193.—Closure of the visceral pleura with an exaggerated Cushing stitch