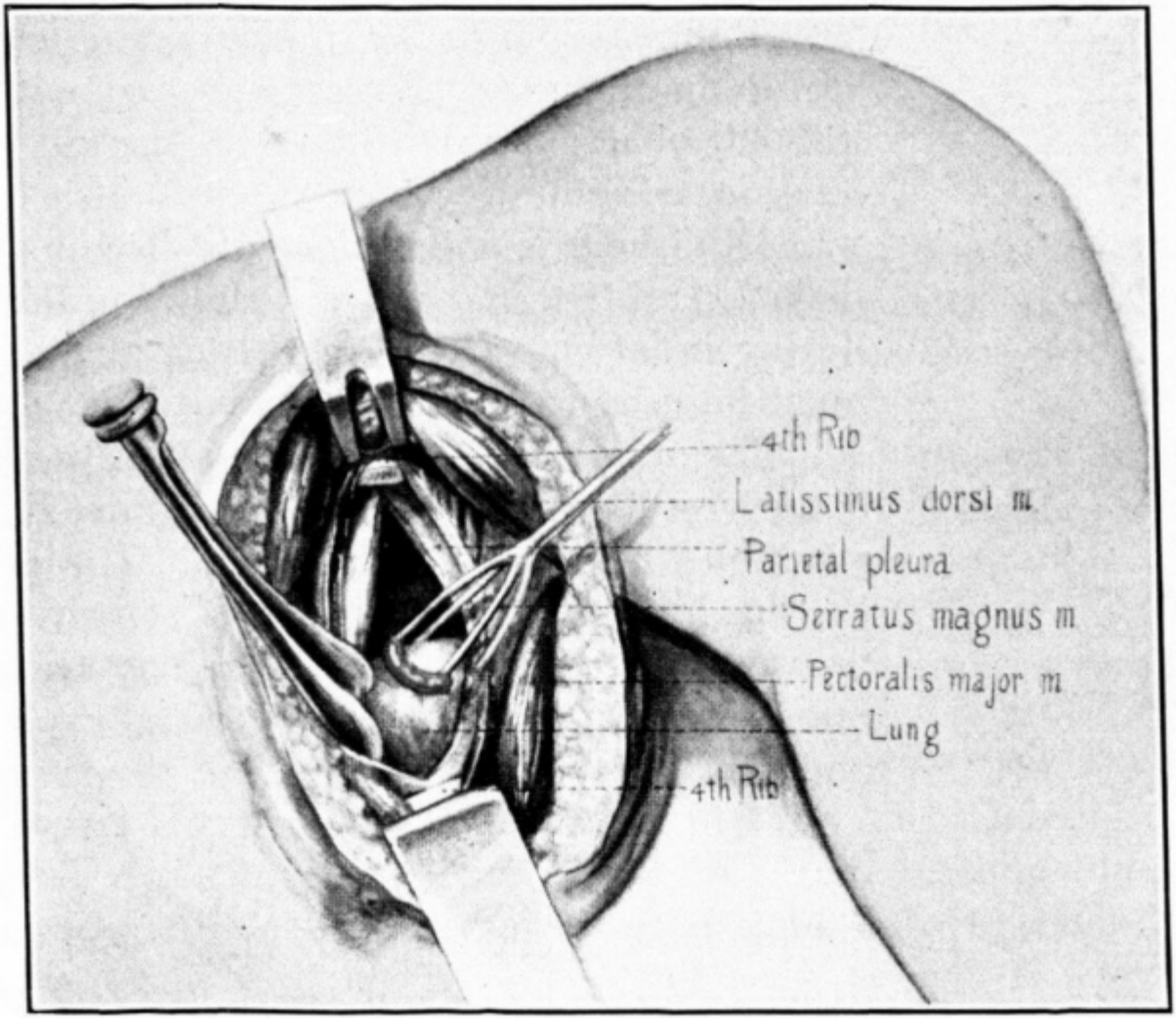

FIG. 191.—Thoracotomy of election. The margin of the deflated lung being guided toward the wound with Tuffier's forceps