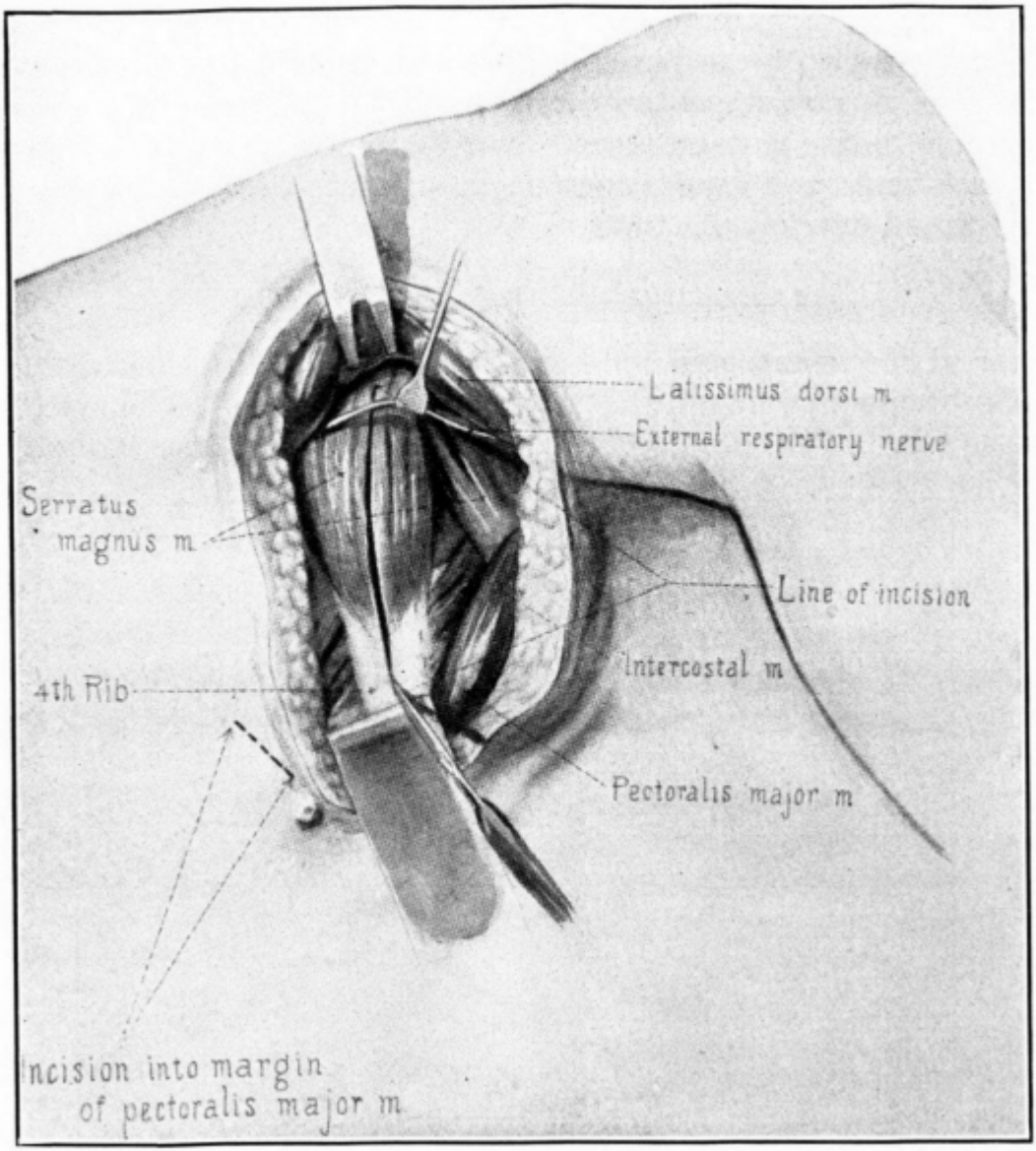

FIG. 184.—Method of exposing a rib for resection. The serratus is excised parallel to its fibers; the long thoracic nerve is retracted posteriorly