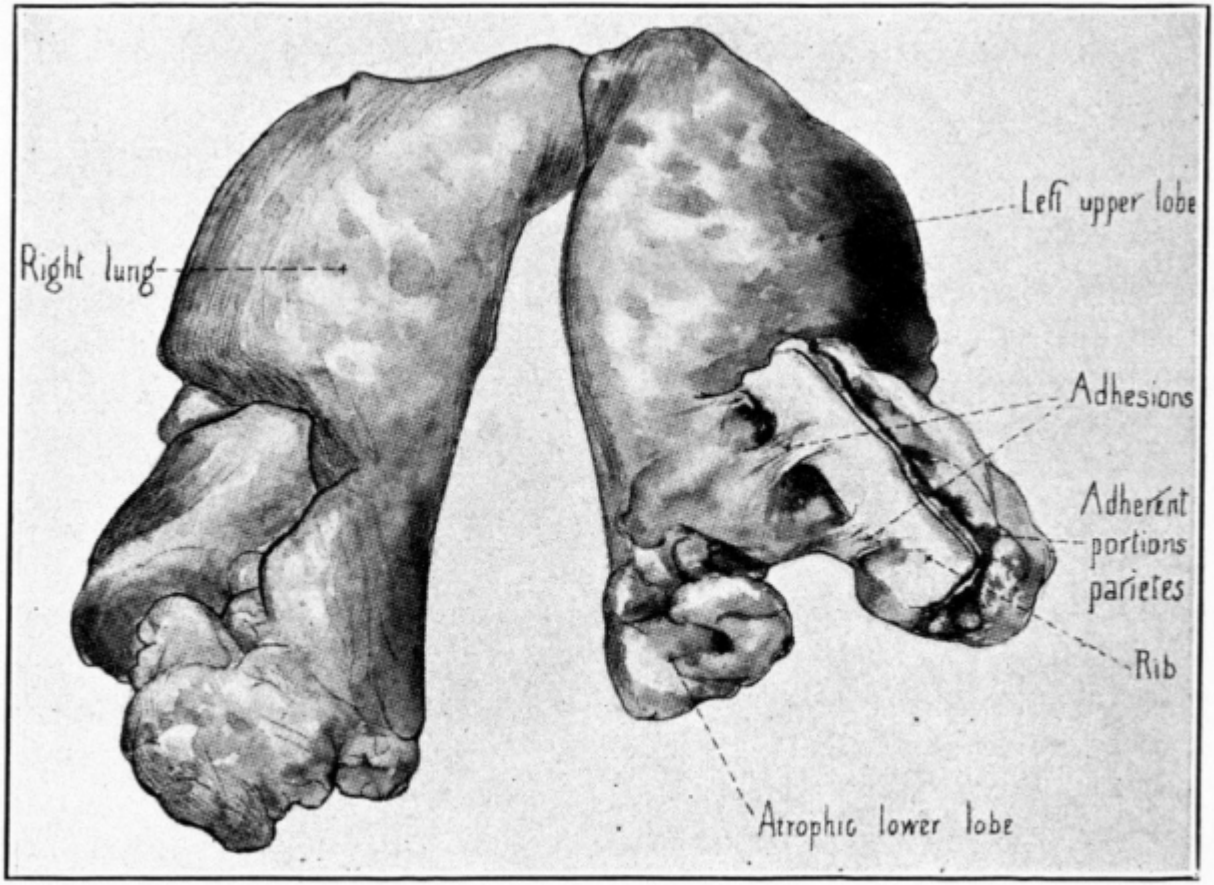

FIG. 182.—Sheep's lung five months after ligation of the artery supplying the inferior margin of the left lower lobe, showing adhesions produced by simple thoracotomy