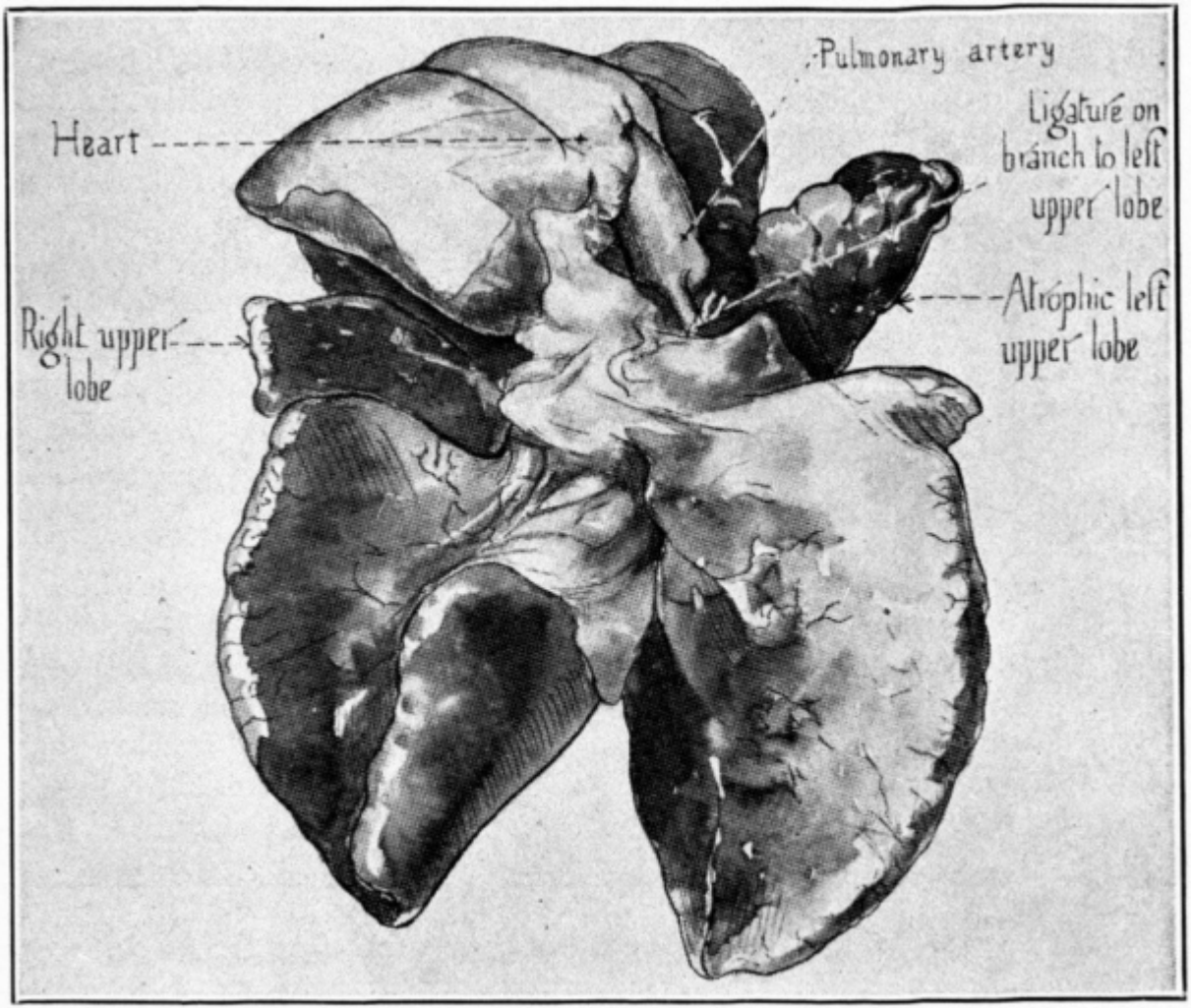

FIG. 181.—Sheep's lung five weeks after ligation of the artery supplying the left upper lobe