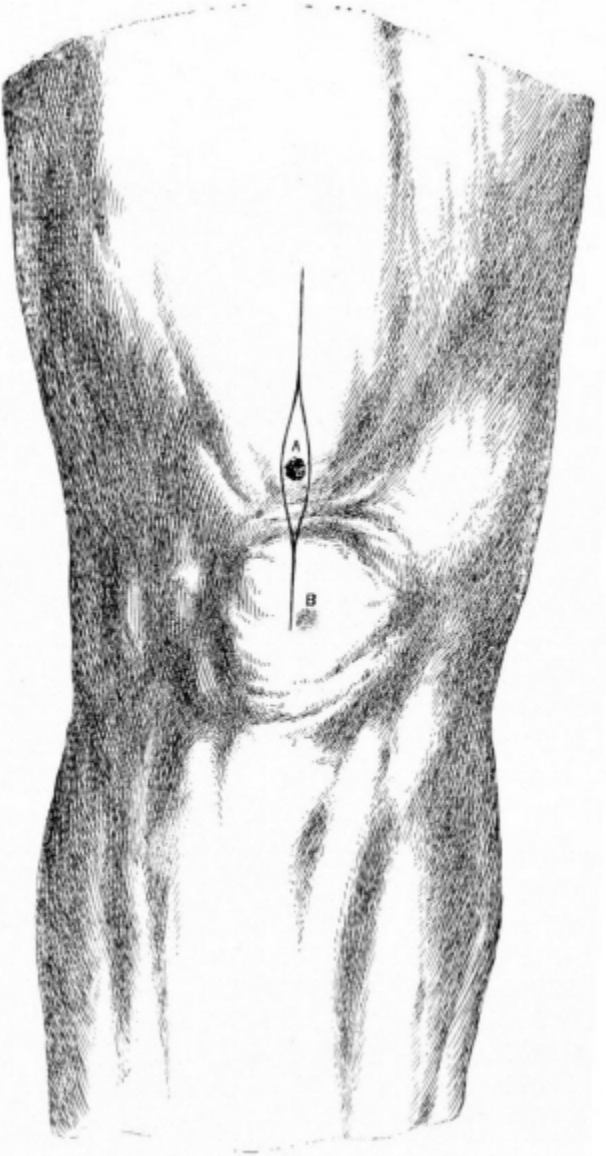


FIG. 178.—Gunshot wound of the knee. A, wound of entrance, incision for débridement; B, situation of foreign body. (Keen's Surgery)