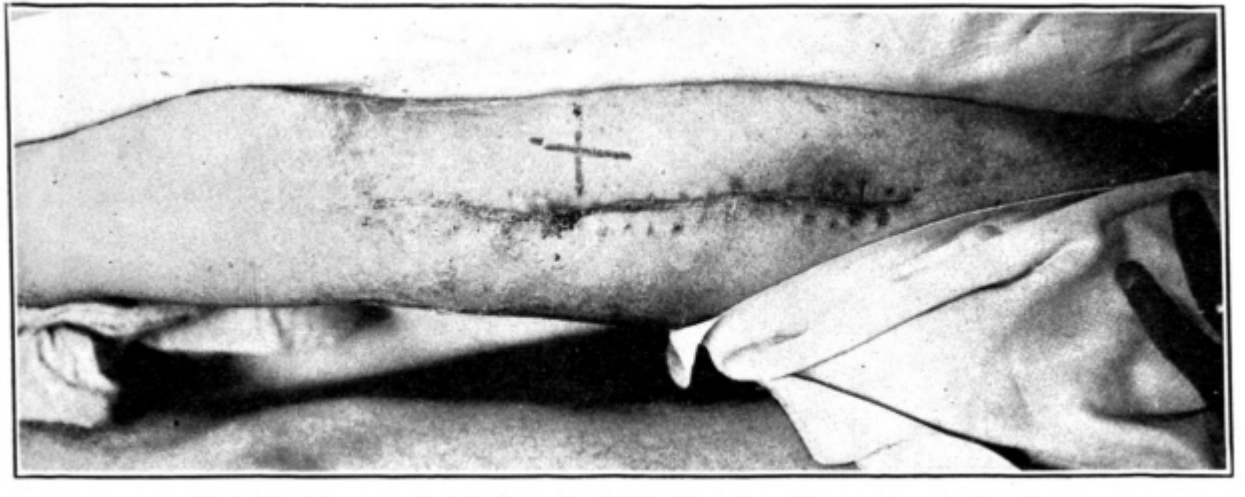

FIG. 171.—Large perforating wound of thigh, closed by primary suture. (Heuer)