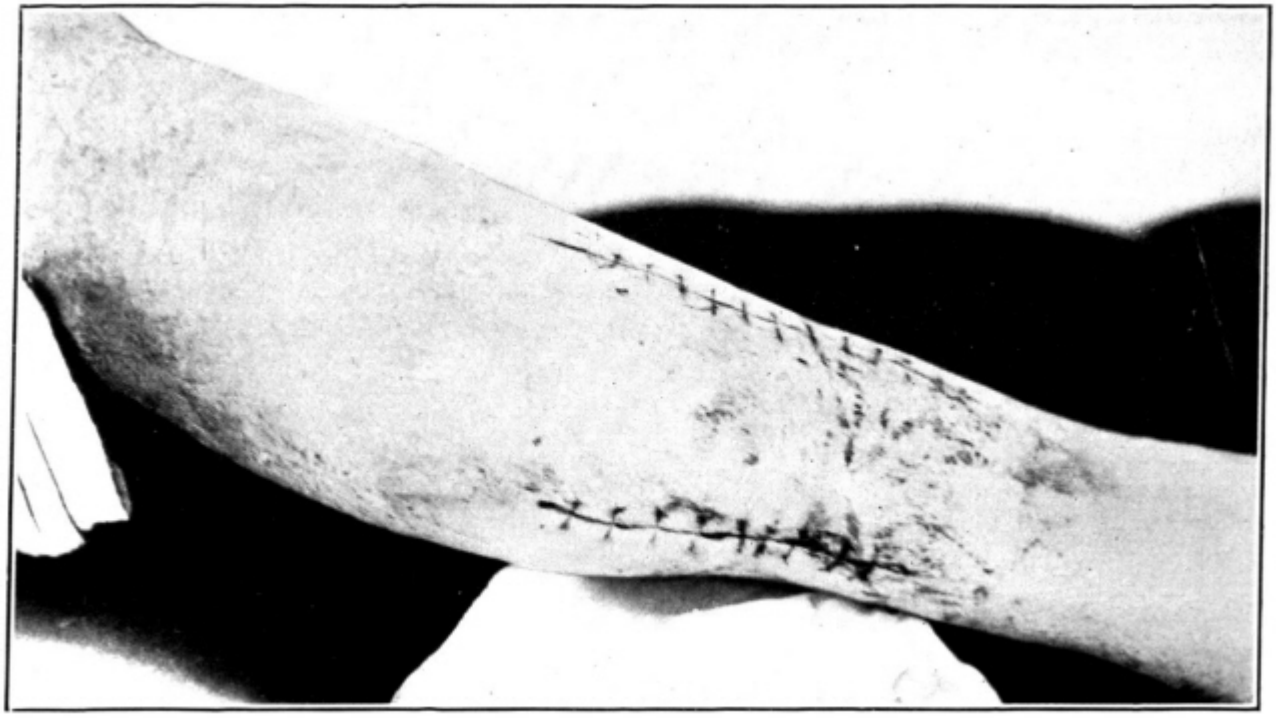

FIG. 170.—Large penetrating shell wound, internal aspect of leg, closed by retarded primary suture. (Heuer)