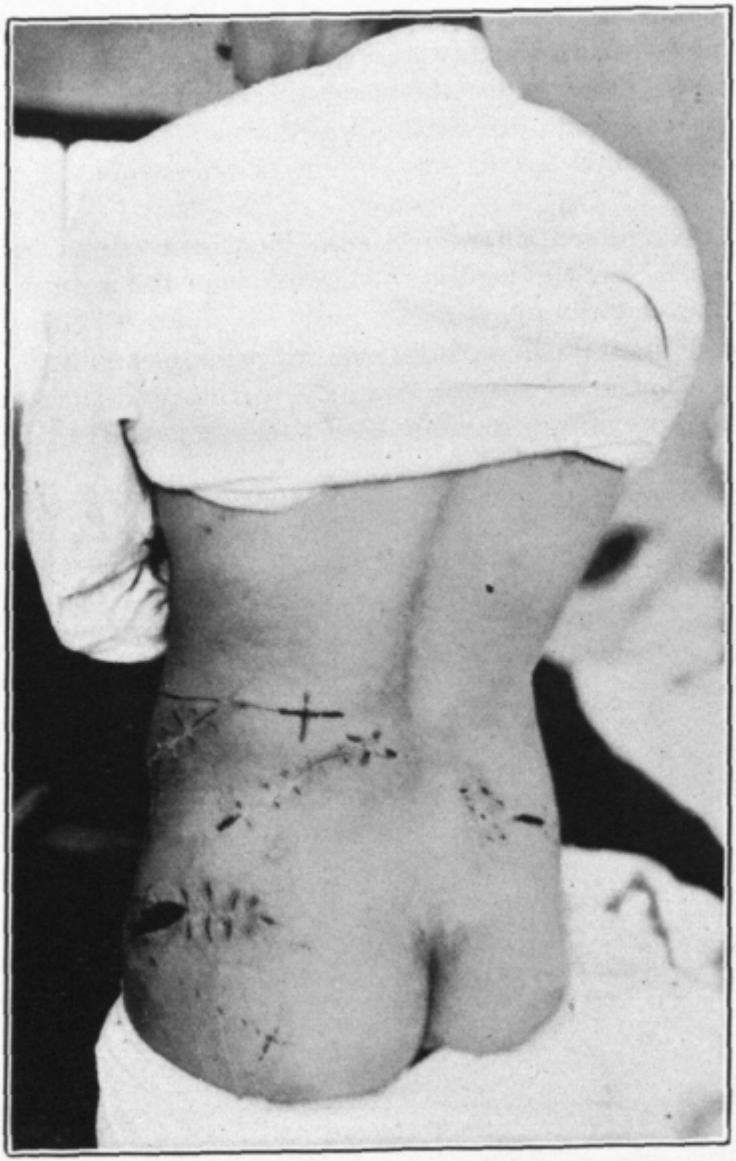

FIG. 165.—Multiple, penetrating wounds of back, soft parts, closed by primary suture. Lower left wound "failure." (Heuer)