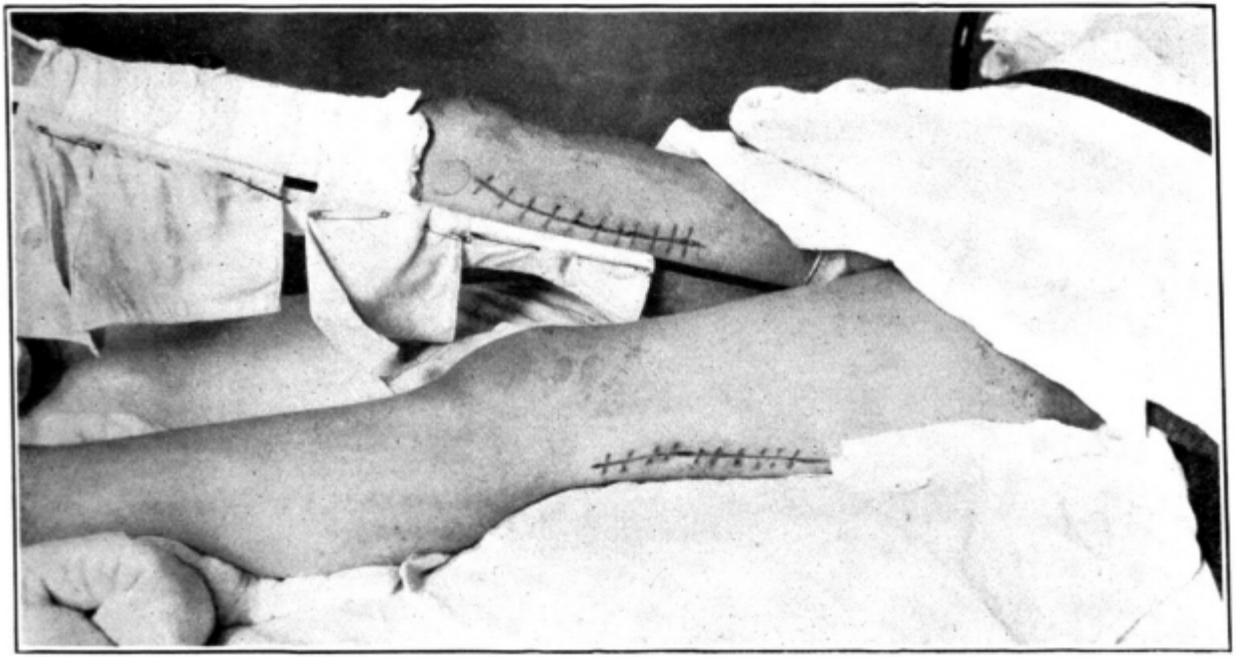

FIG. 164.—Perforating shell wound, left thigh, the same missile penetrating right thigh and fracturing right femur. All wounds closed by primary suture. (Heuer, Keen's Surgery)