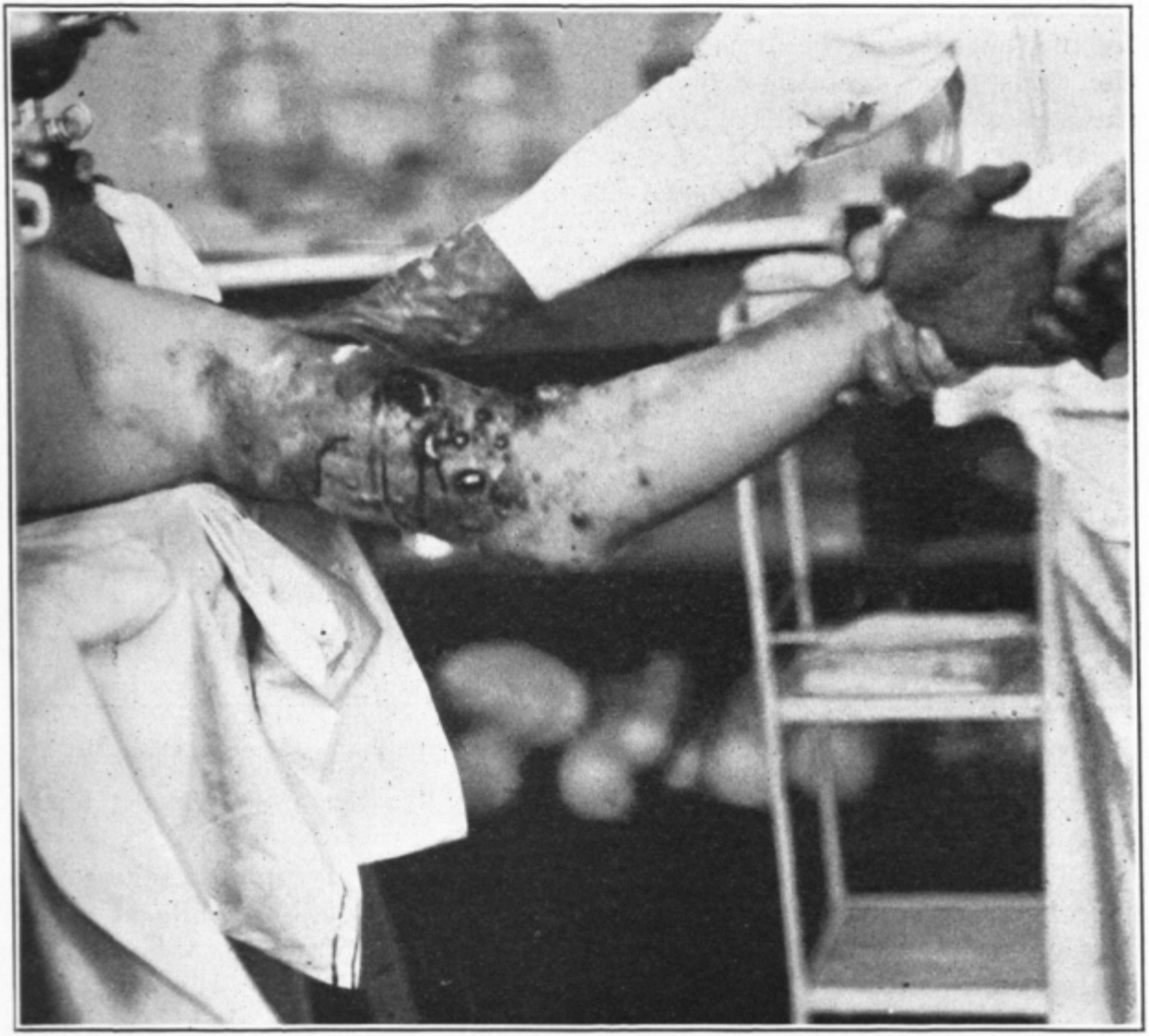

FIG. 157.—Gas gangrene of arm before operation. (Courtesy of Maj. Benjamin Jablons, M. C.)