

Patient John Smith \_\_\_\_\_ Right Left

Address B.H. 115 \_\_\_\_\_

Surgeon X.Y. Jones \_\_\_\_\_

Date June 19, 1918 \_\_\_\_\_

Radiologist:

D.E.M. \_\_\_\_\_

SIZE OF BODY 3 mm Dye \_\_\_\_\_ by \_\_\_\_\_ by \_\_\_\_\_ mm.

**LOCATION**

**First Exposure—Side View**

- \_\_\_\_\_ **S** mm. Above Horizontal Plane of Cornea.
- \_\_\_\_\_ **mm.** Below Horizontal Plane of Cornea.

**Second Exposure—Horizontal Section**

- \_\_\_\_\_ **mm.** Temporal Side Vertical Plane of Cornea.
- \_\_\_\_\_ **S** mm. Nasal Side Vertical Plane of Cornea.
- \_\_\_\_\_ **12 1/2** mm. Back of Center of Cornea.

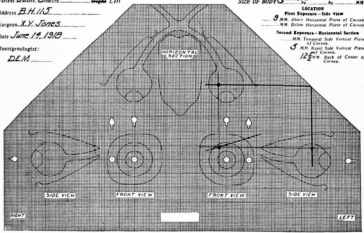


FIG. 153.—Chart used in eye localization