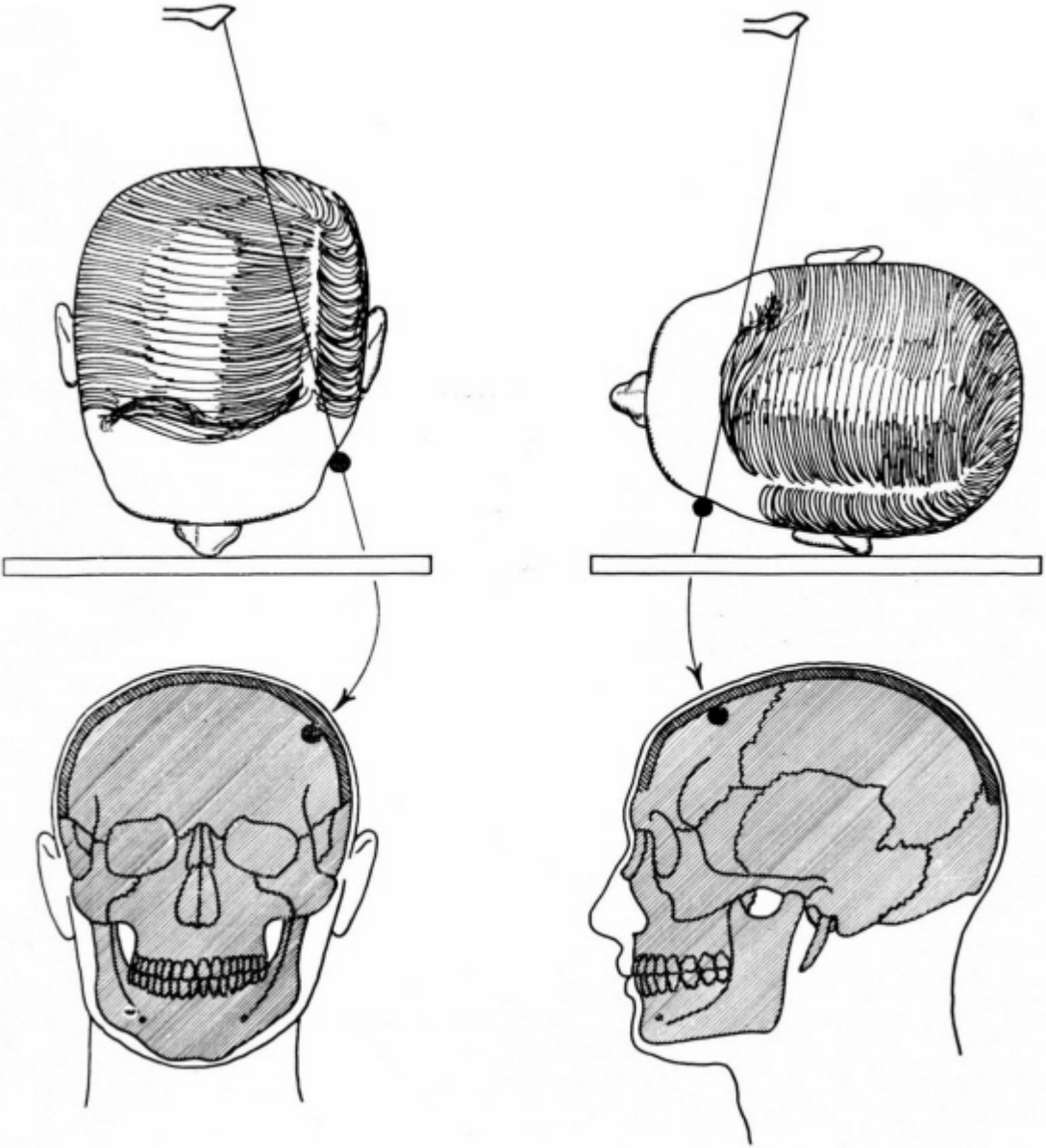

Fig. 113.—Screen appearance which might lead to an erroneous diagnosis of intracranial foreign body