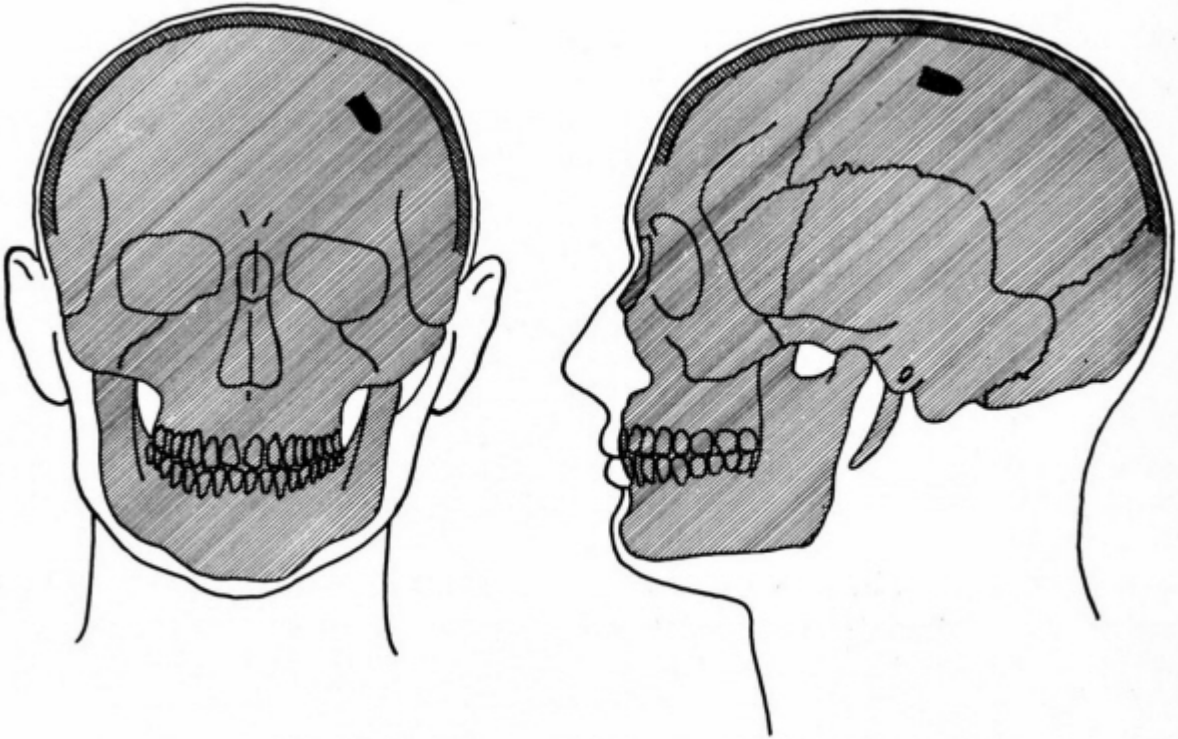

FIG. 112.—Screen appearance of an intracranial foreign body